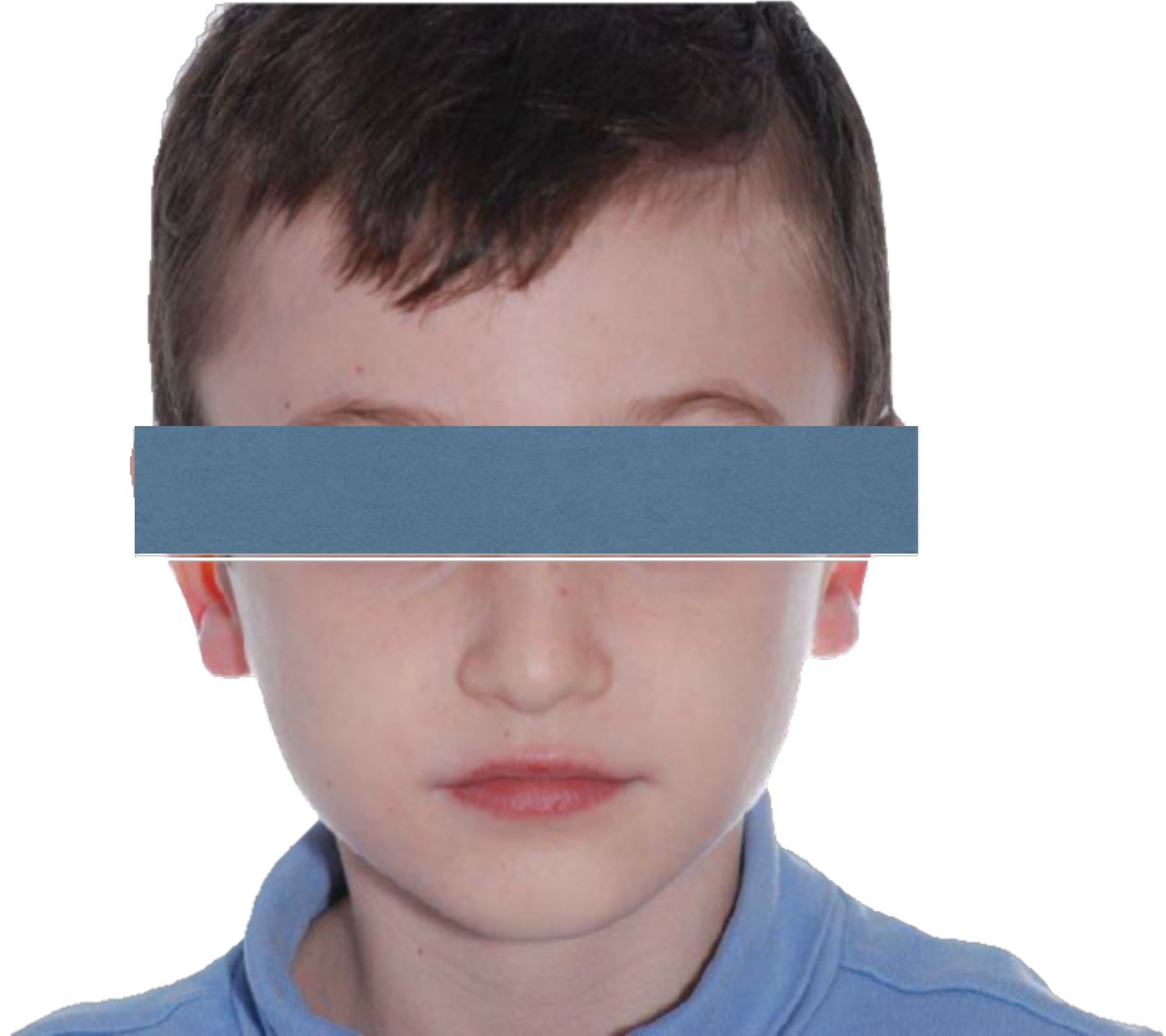

***DDS Filippo Cardarelli***  
*Dentist*  
*Specialist in Orthodontics*  
*University of Milan*

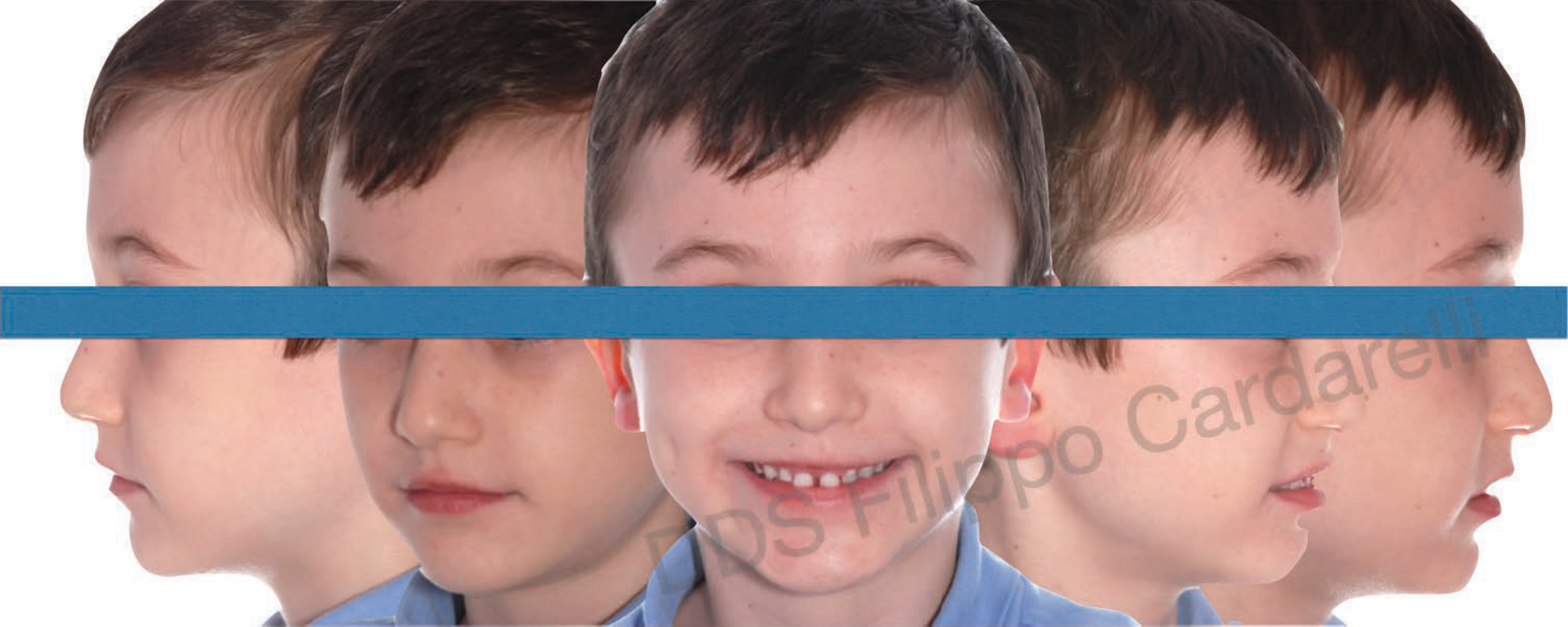

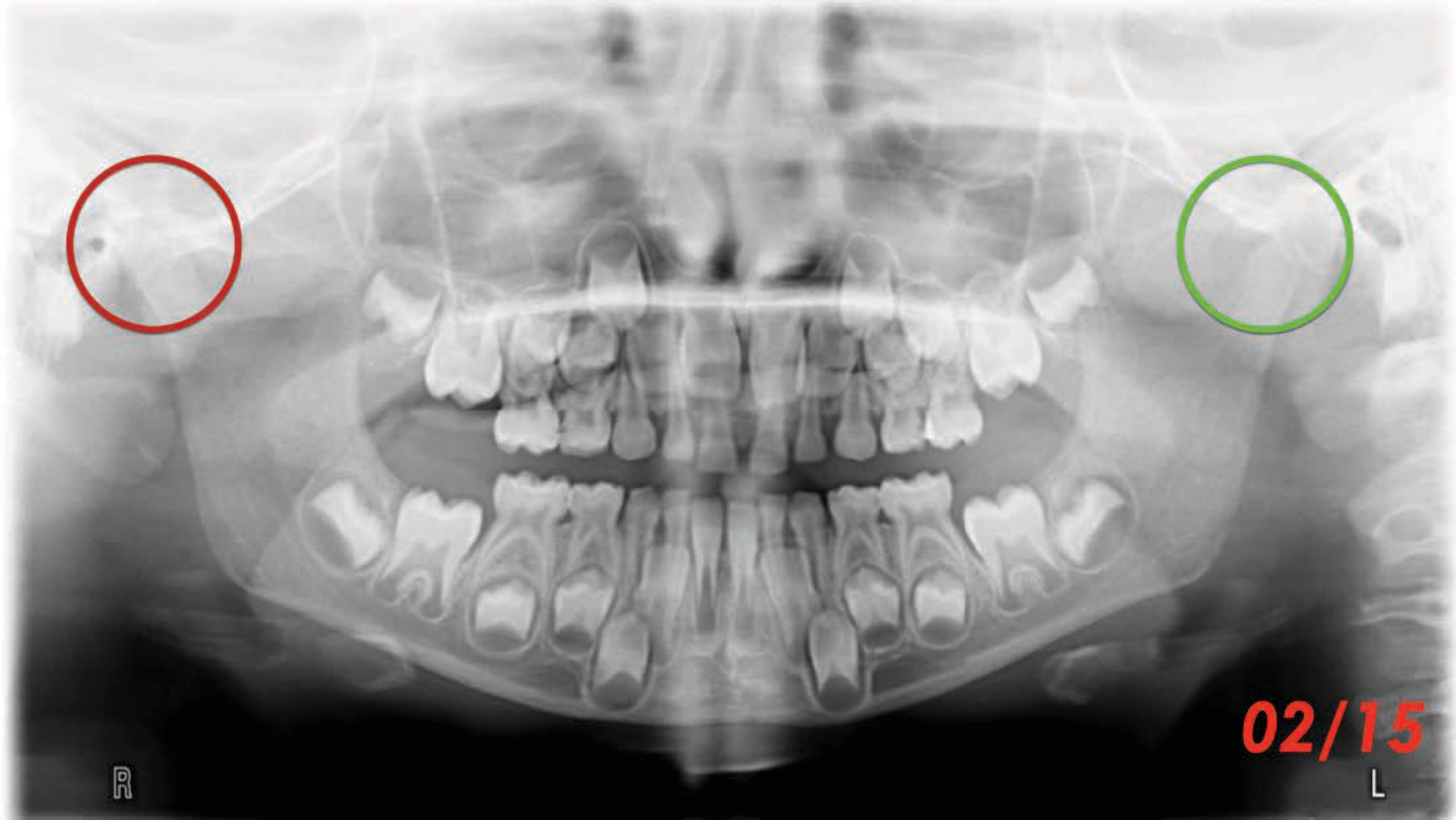# II<sup>nd</sup> Class

Patient 5 years old, Class II deep dental bite, spoiled habit (onychophagia), short labial frenulum. ***The therapeutic sequence involves the following steps:***

- motivation
- vestibular frenectomy
- elastodontic therapy I step at 5 years of age
- elastodontic therapy II Step at 8

DDS Filippo Cardarelli

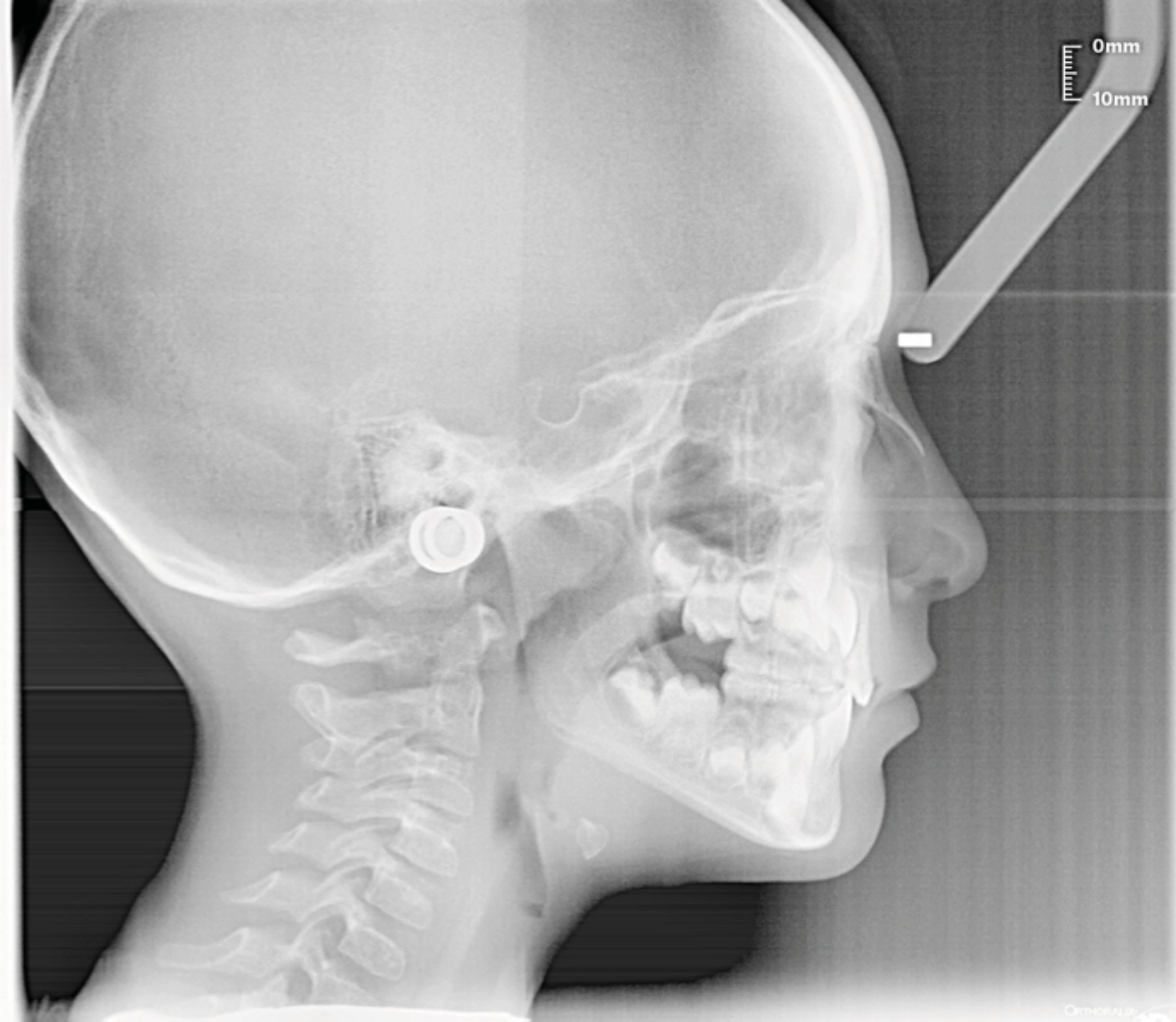




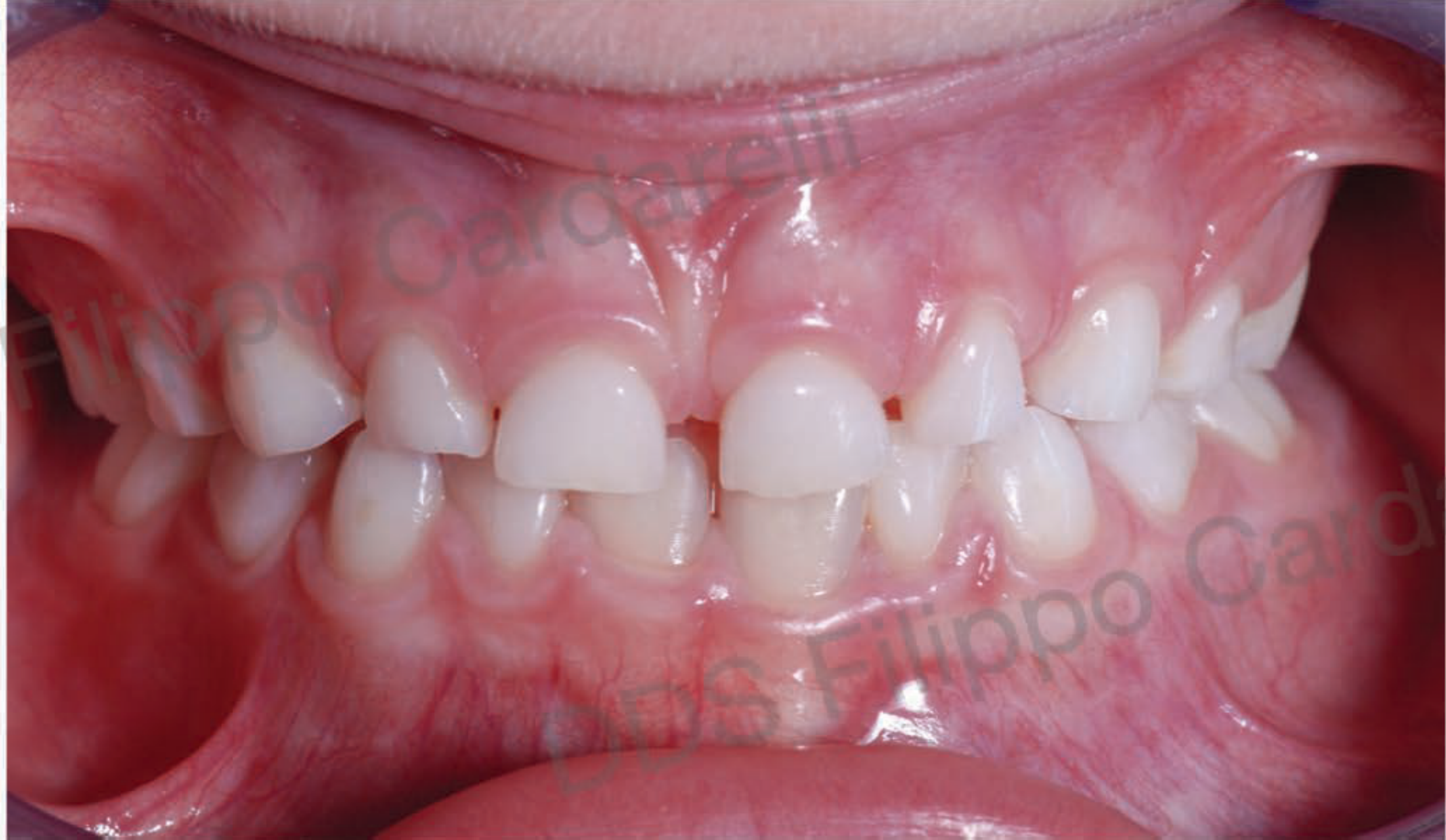R

02/15

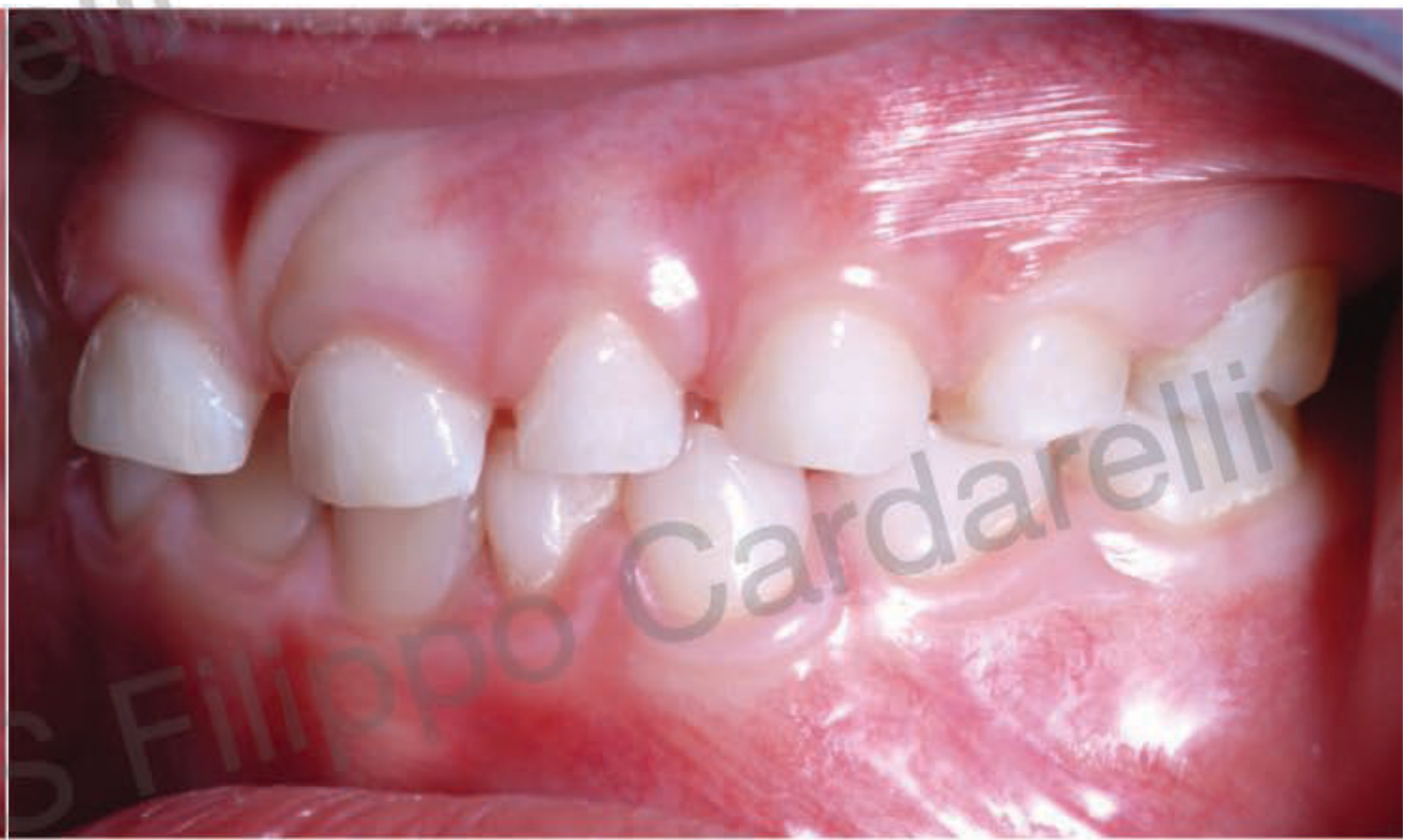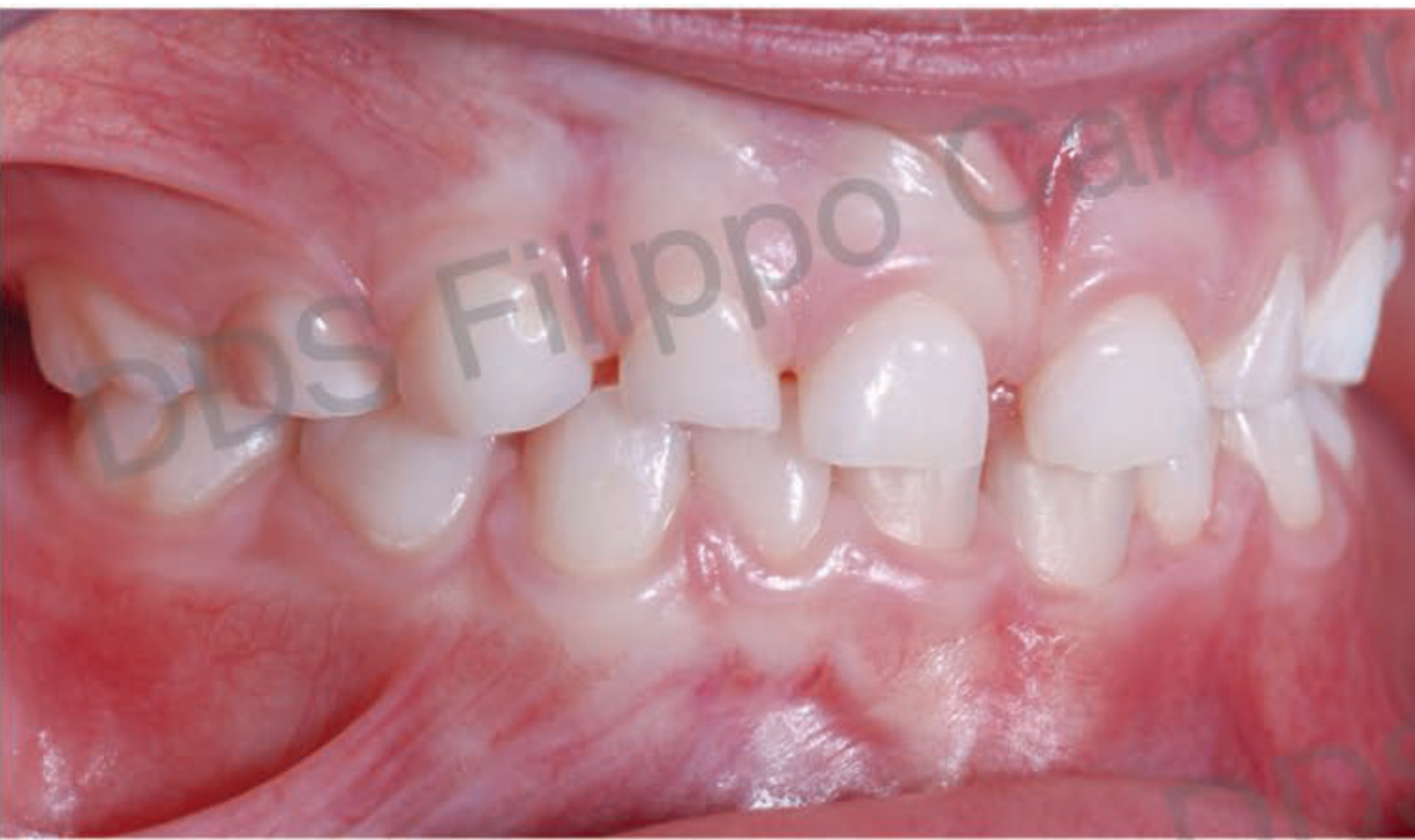L



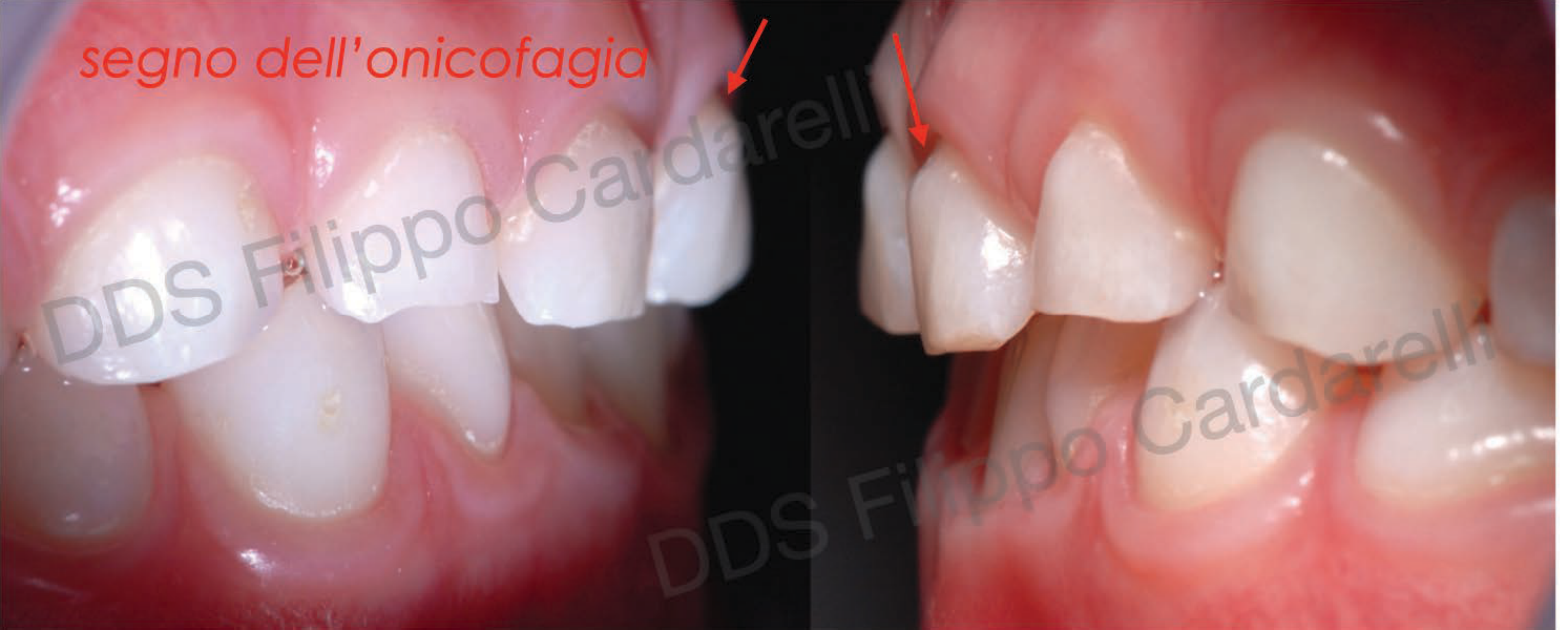DDS



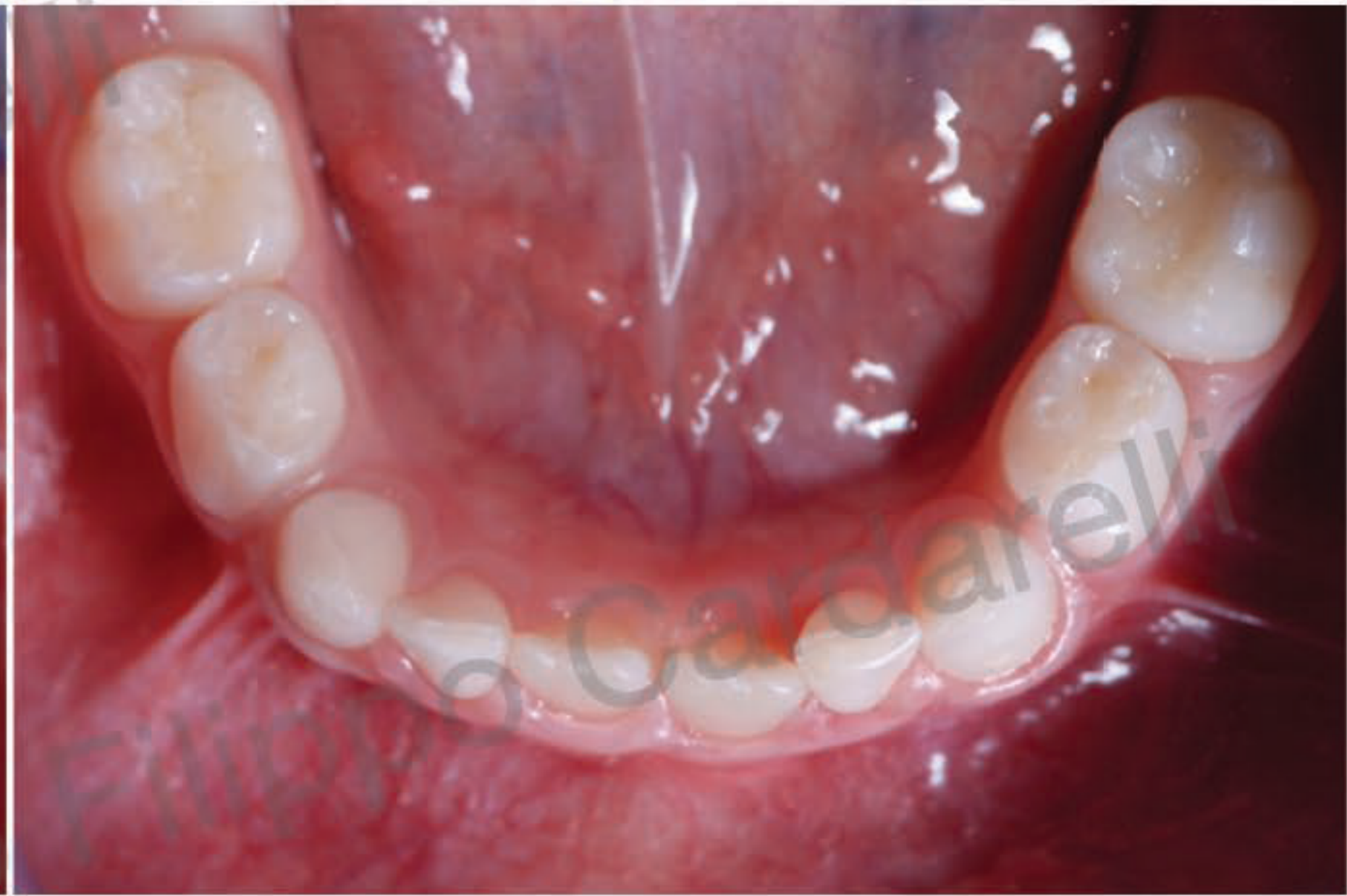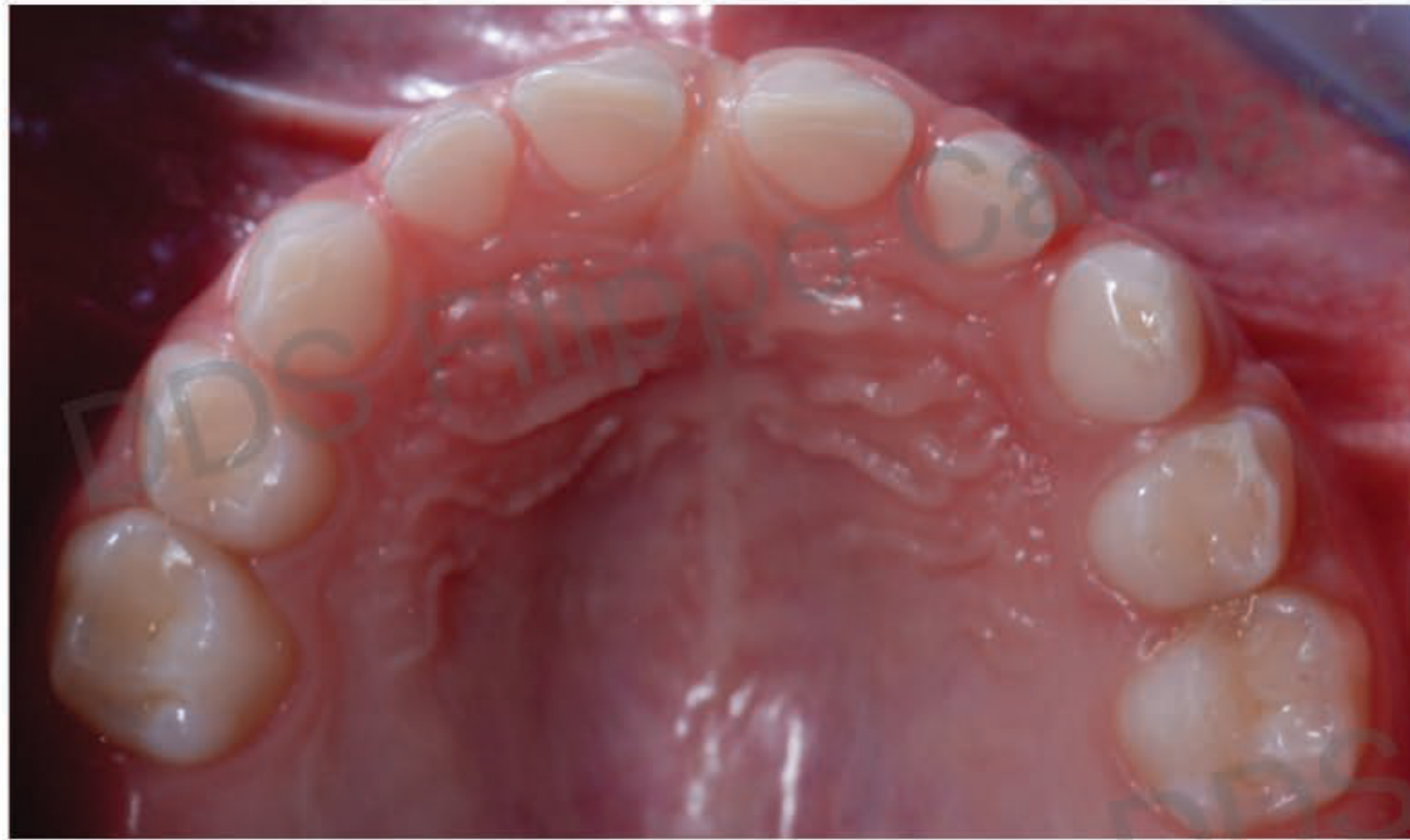
Filippo Cardarelli

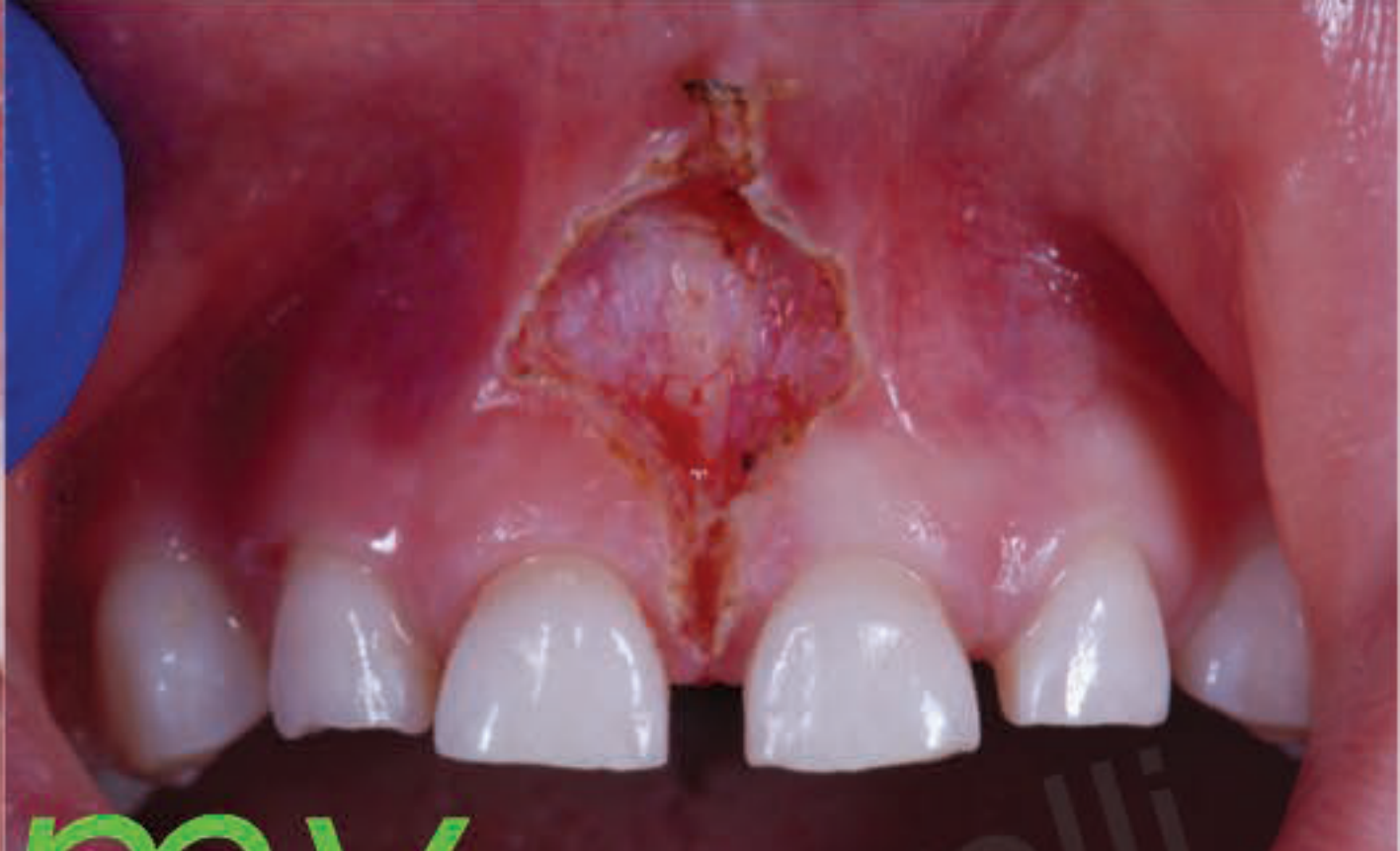
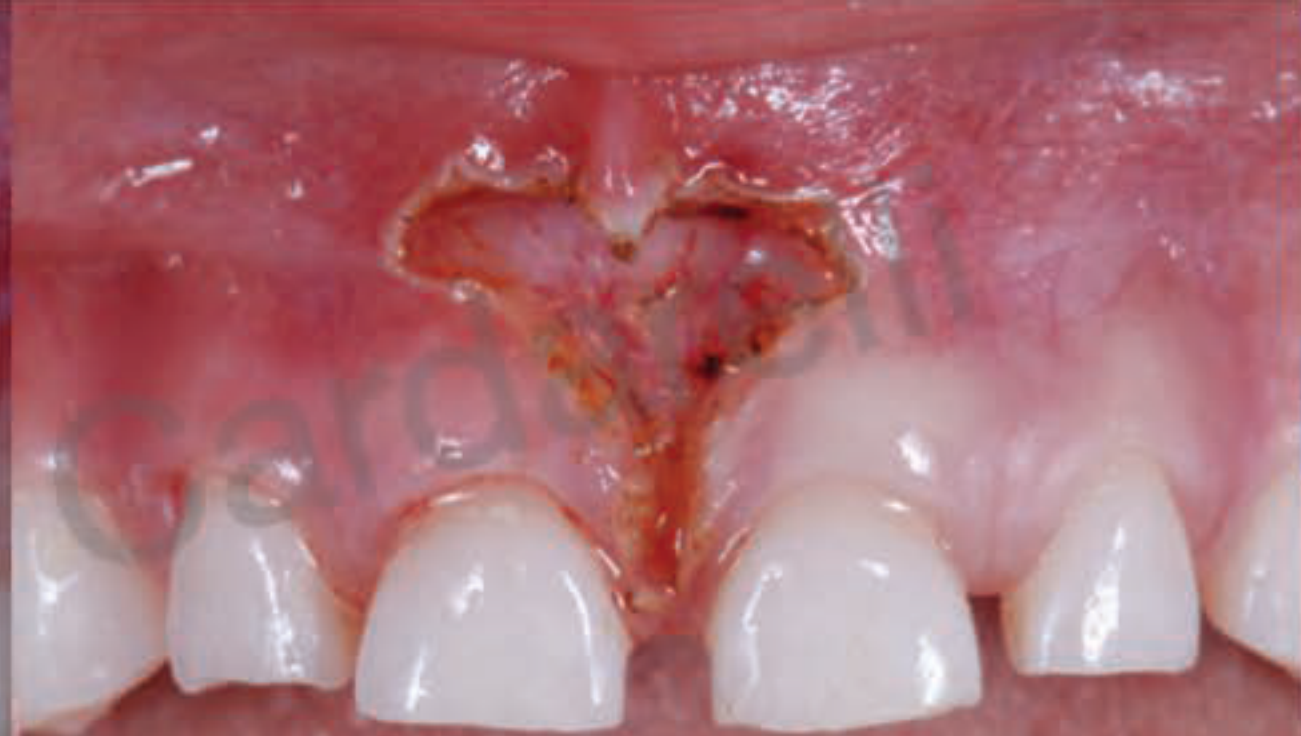
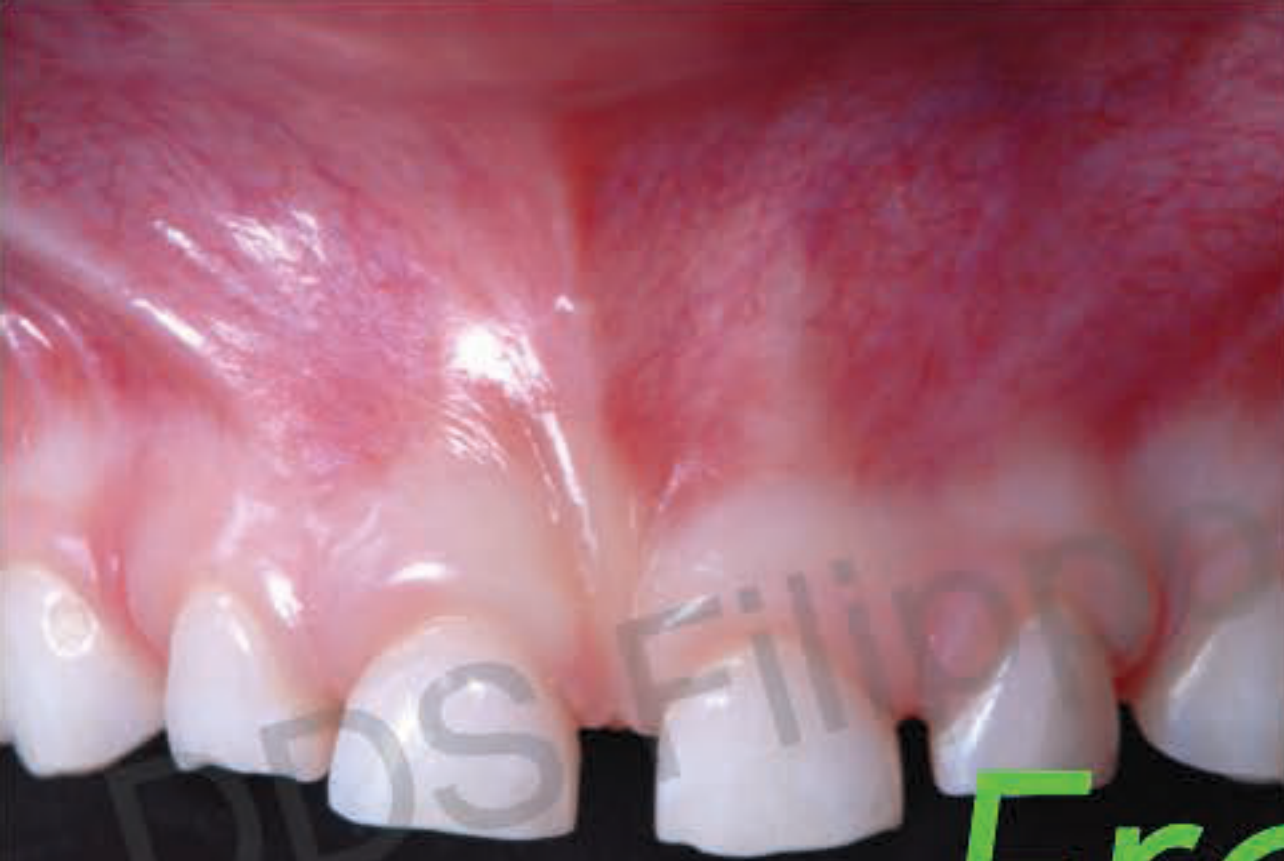*segno dell'onicofagia*

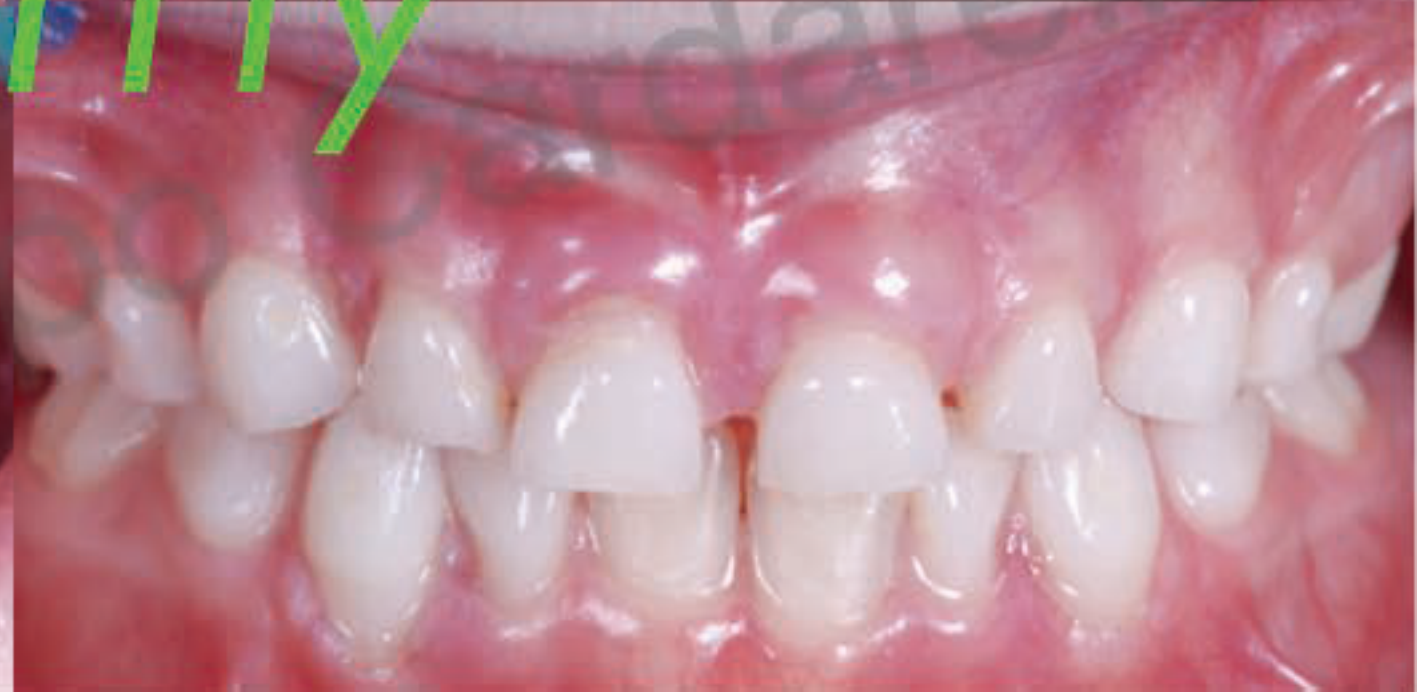
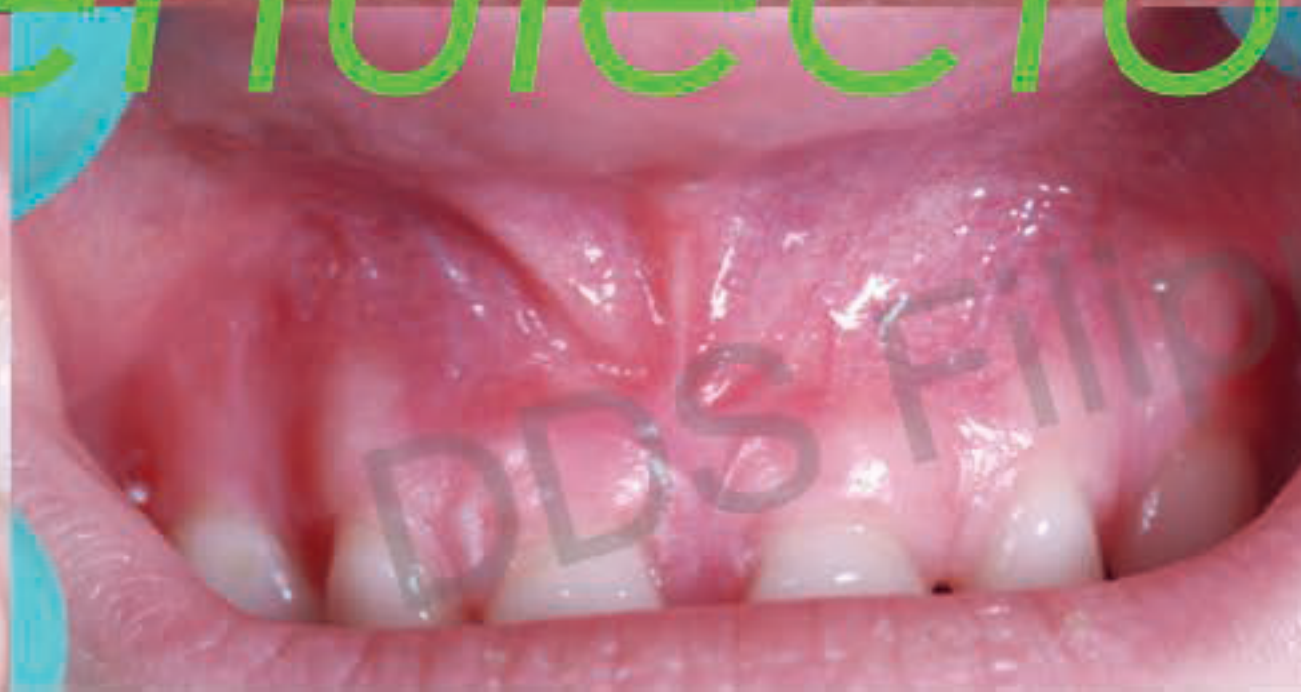
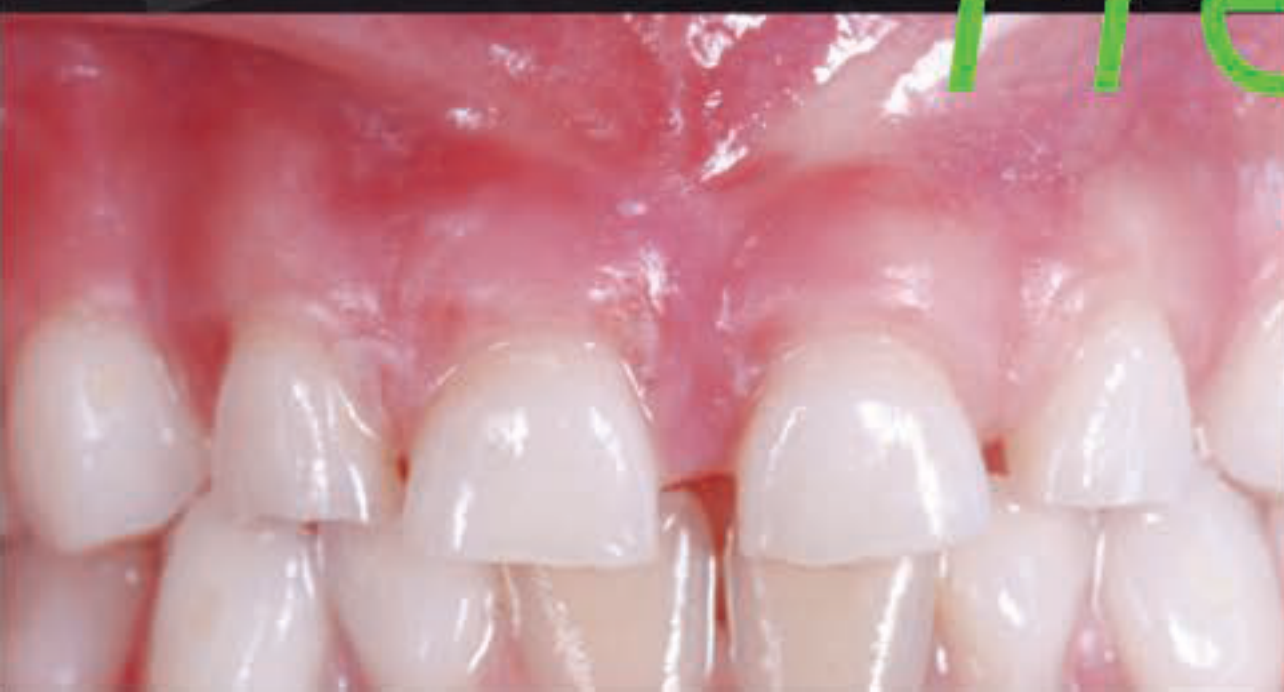


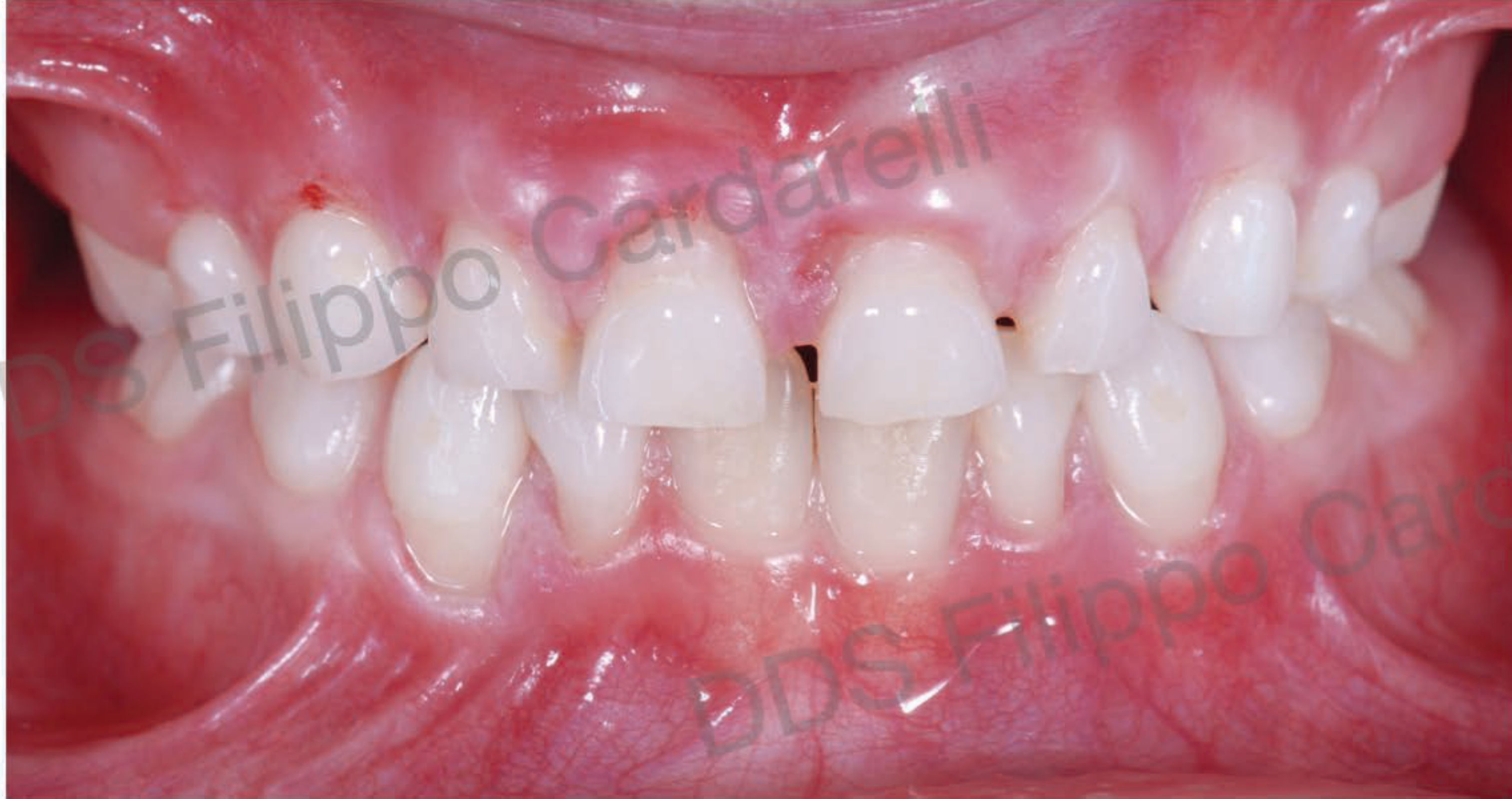


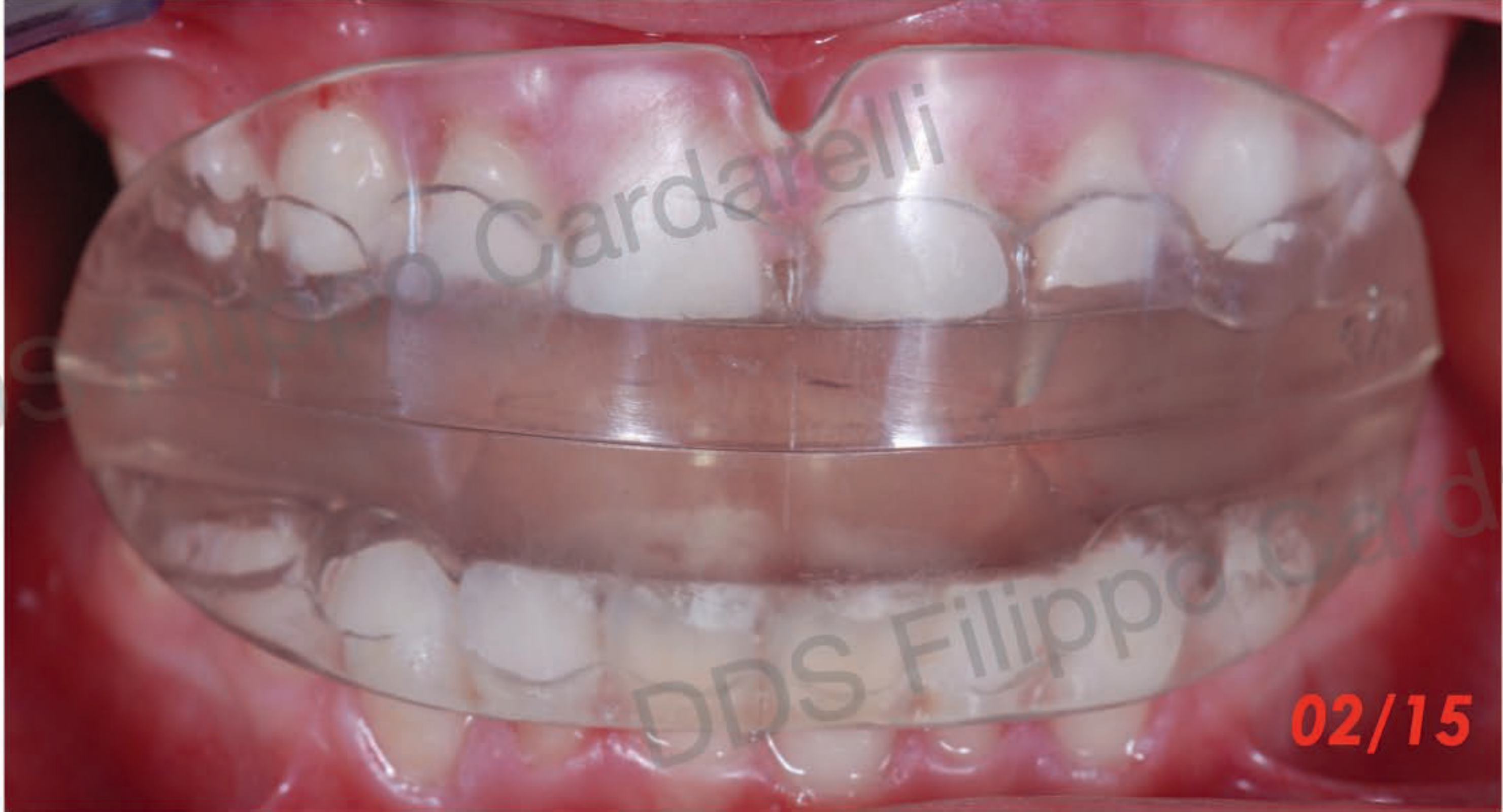# Frenulectomy







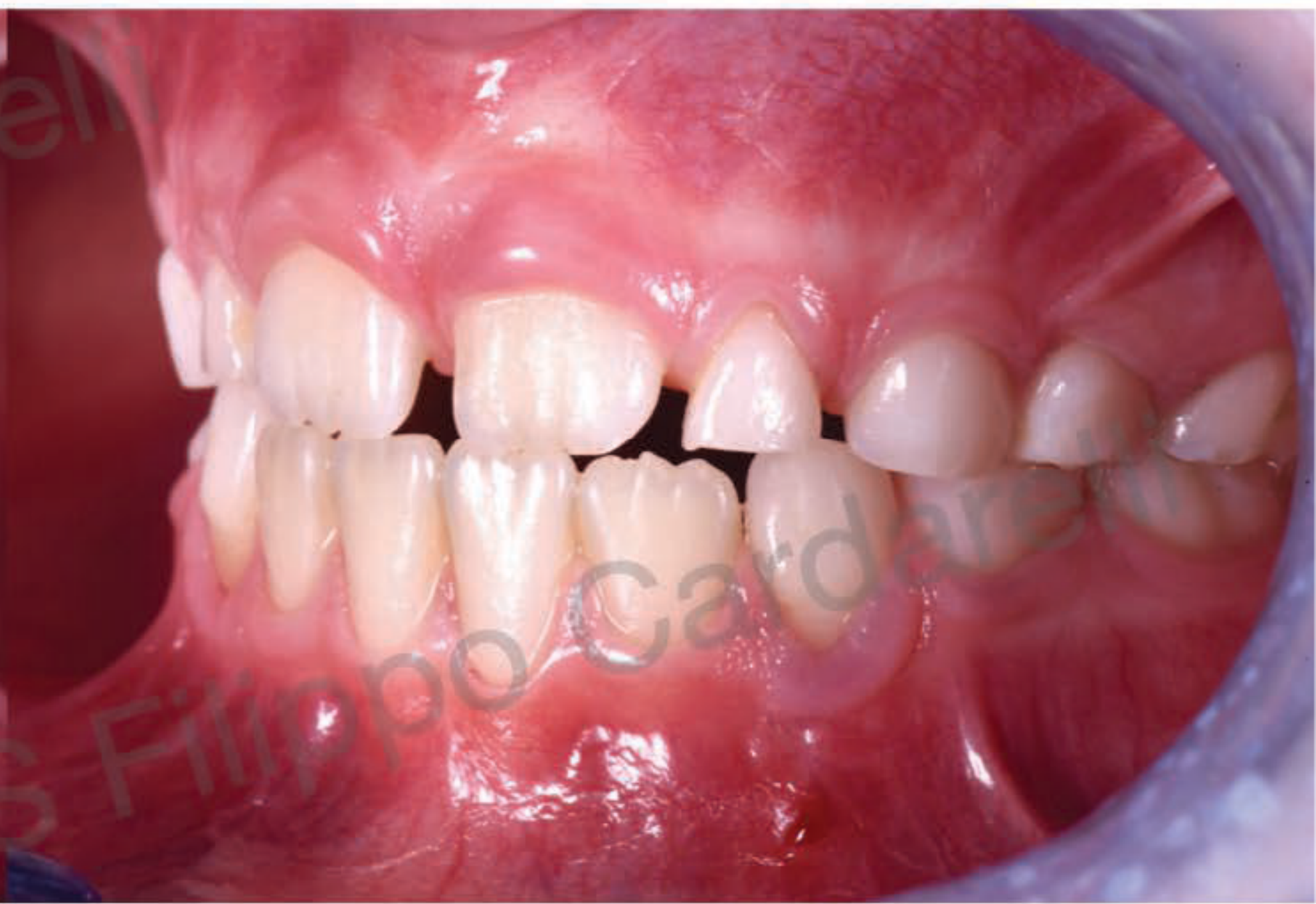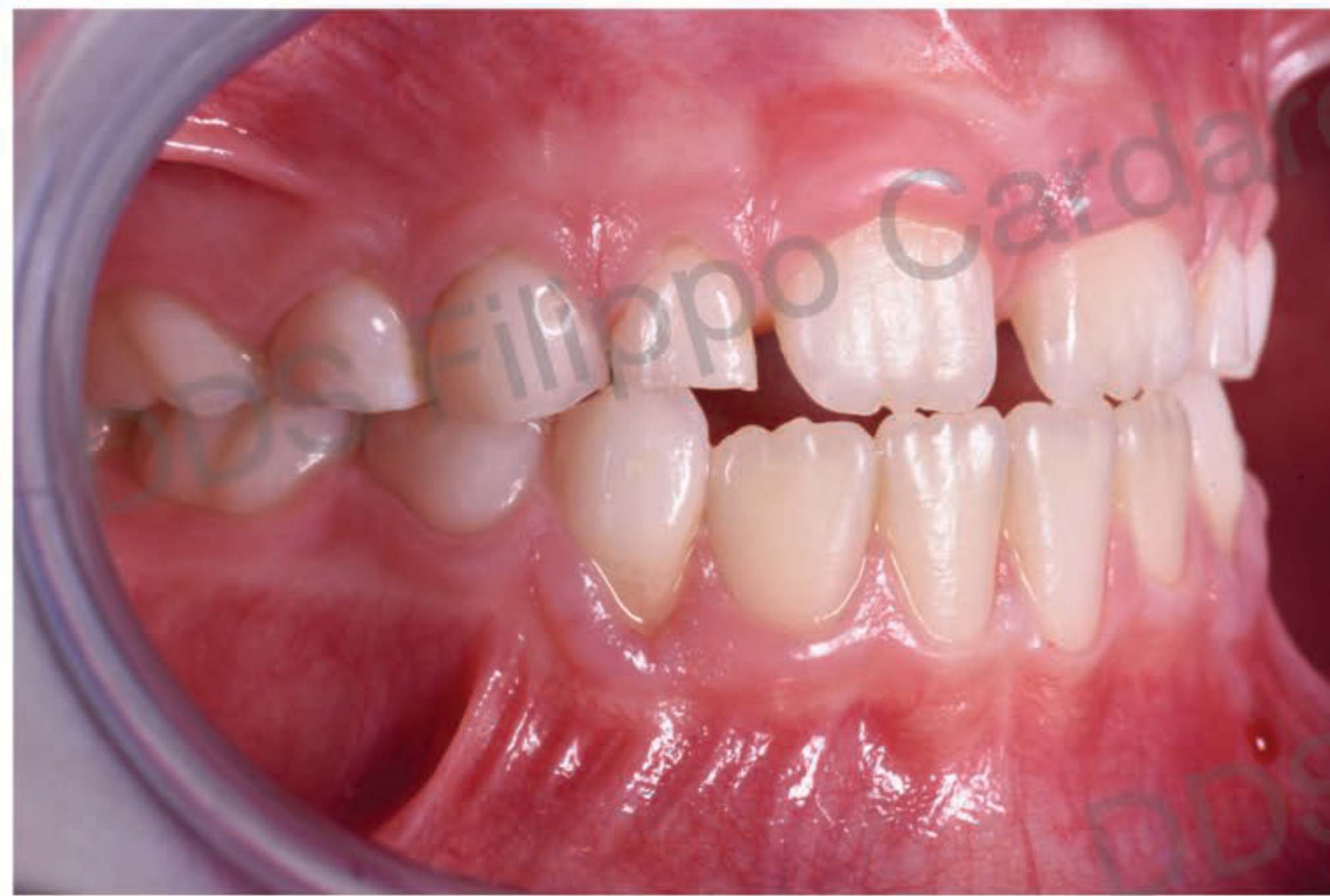DDS

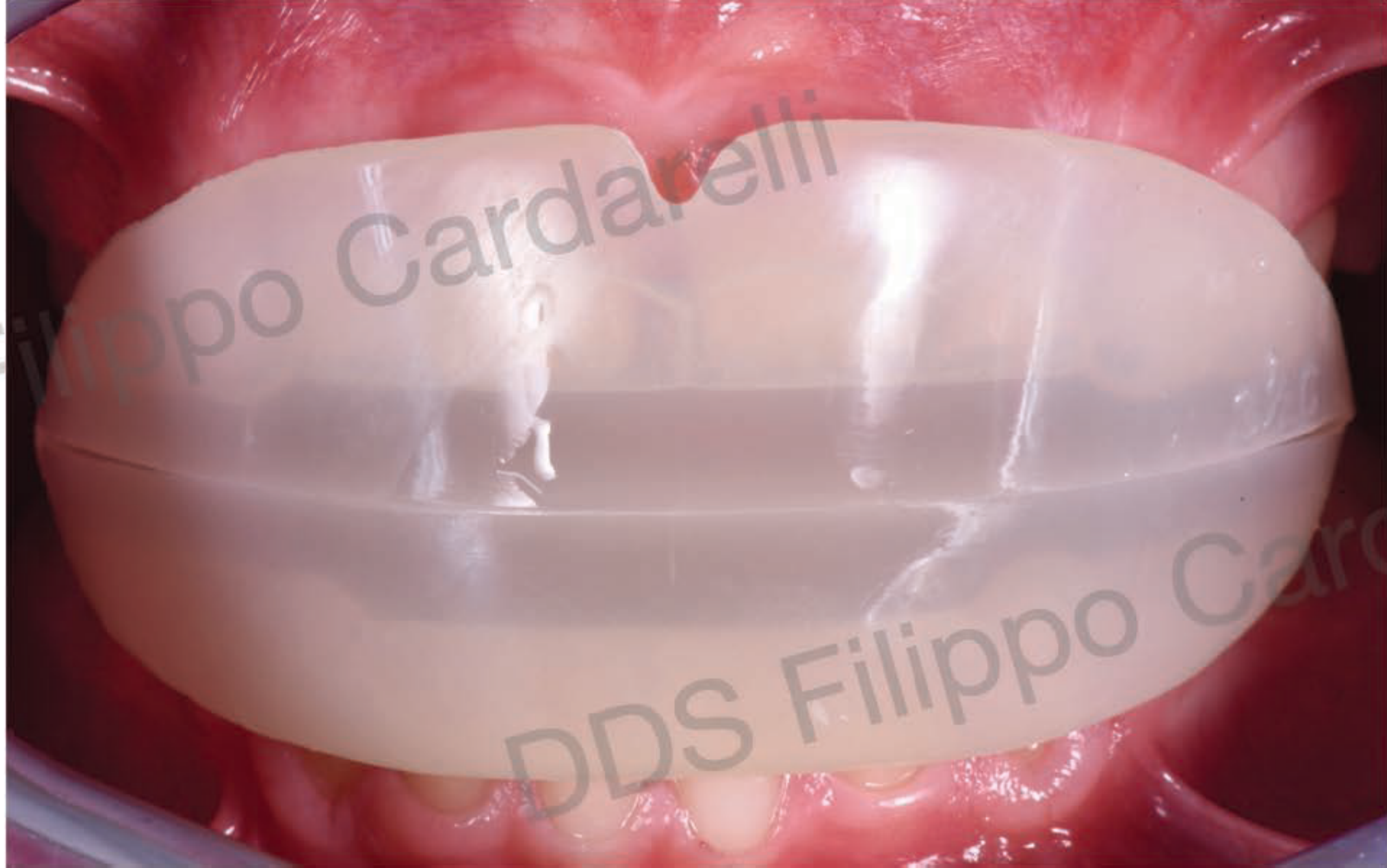Filippo Cardarelli

DDS Filippo Cardarelli

Cardarelli

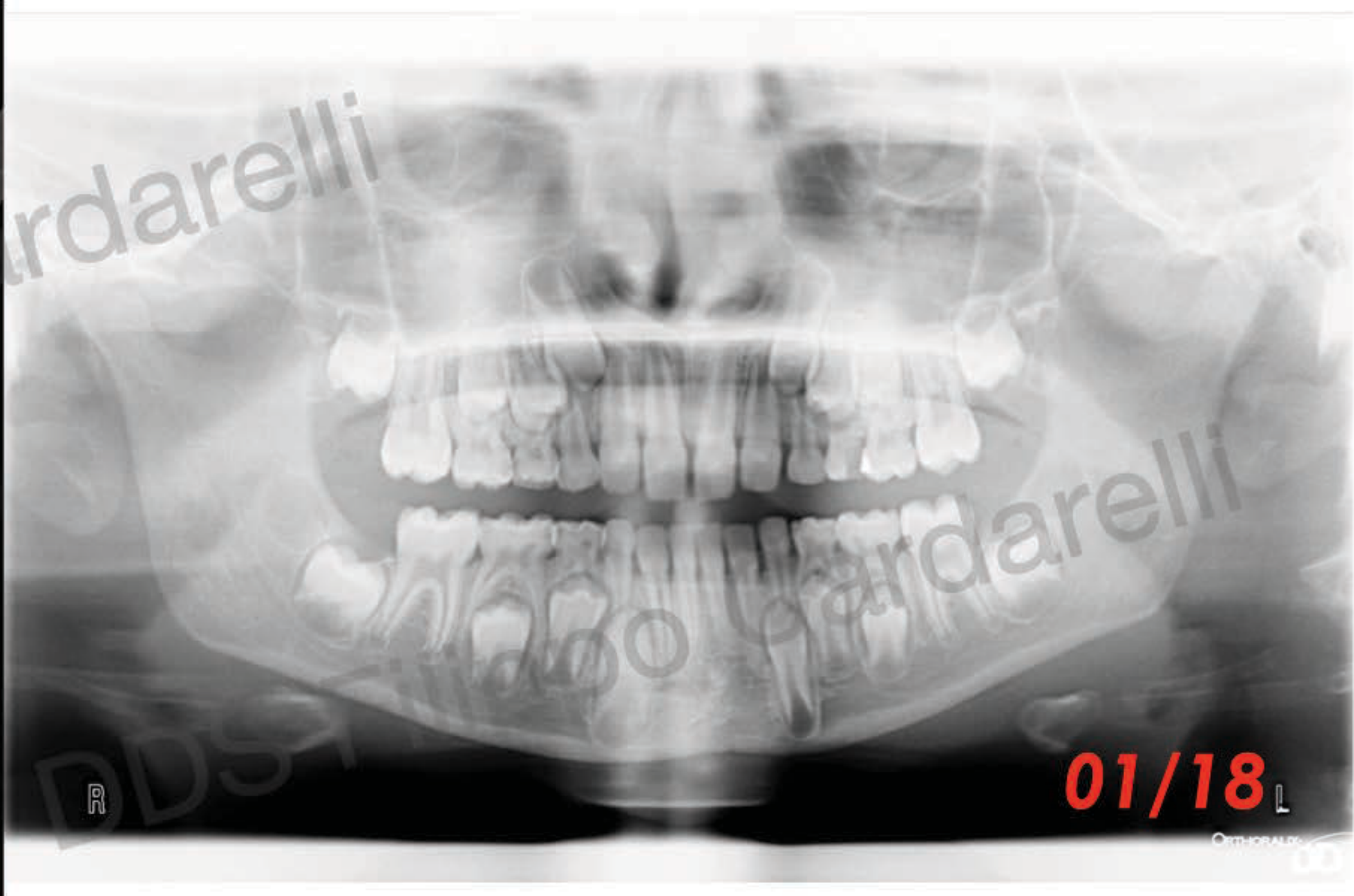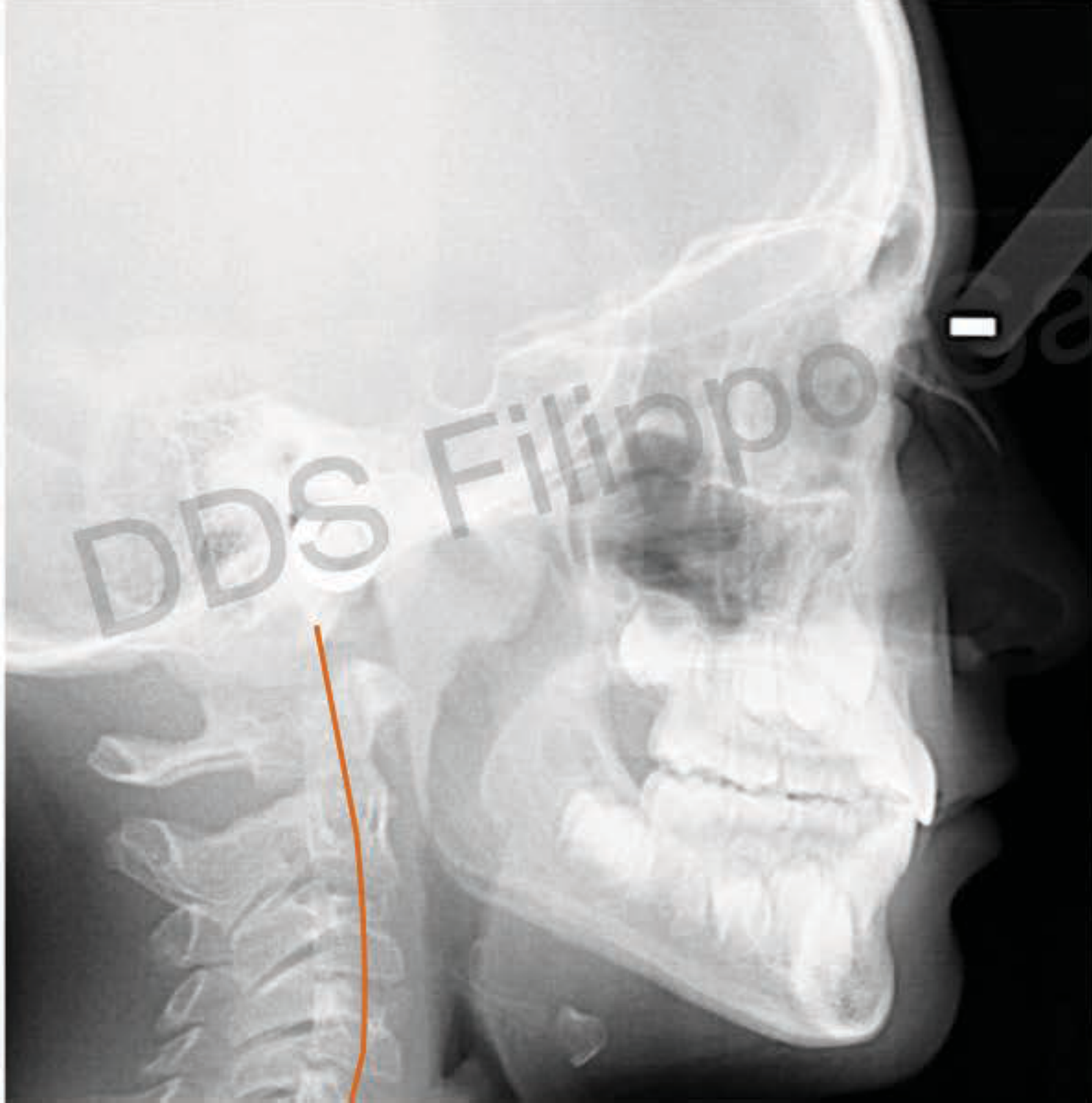
02/15

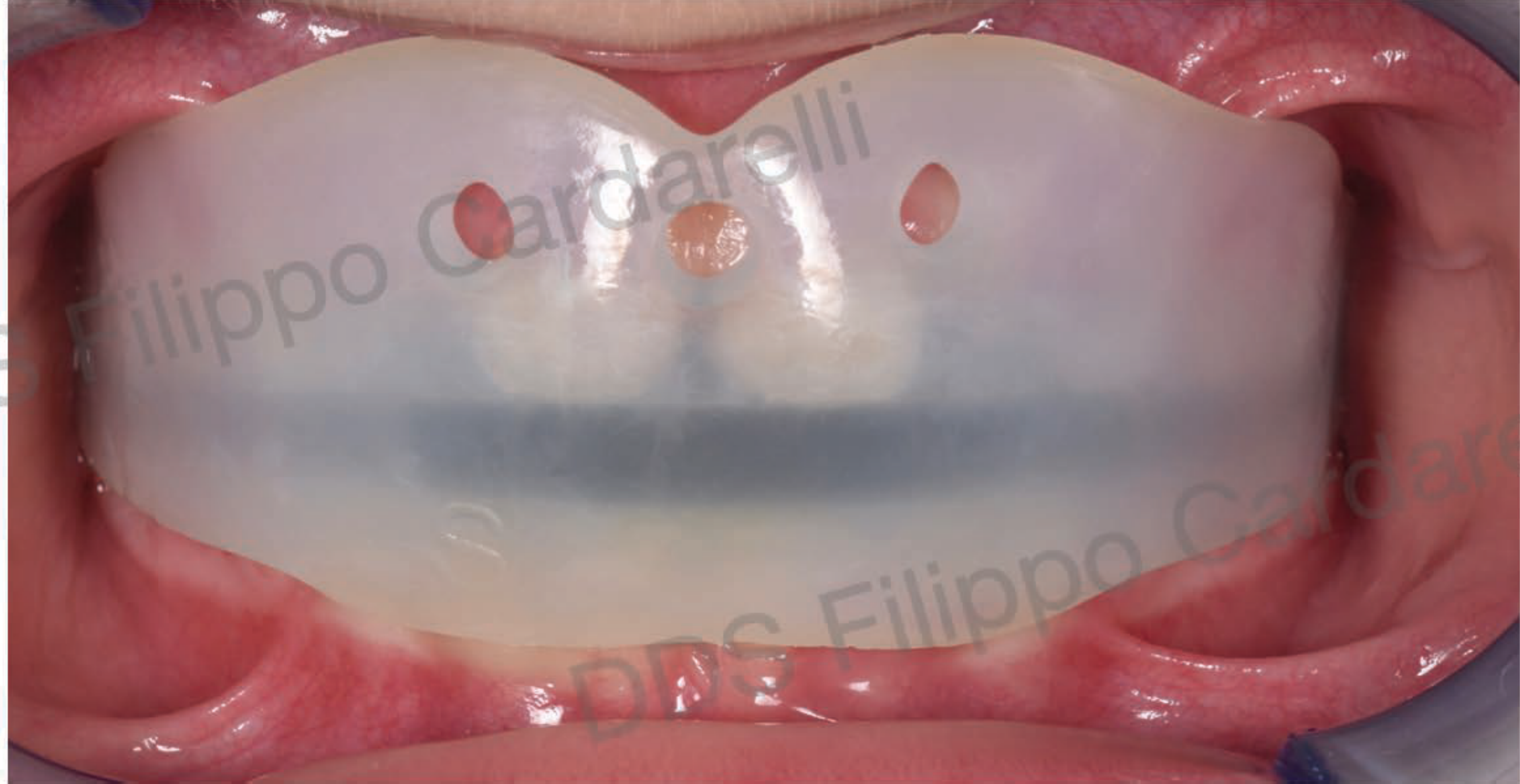



DDS Filippo Cardarelli

DDS Filippo Cardarelli





DDS

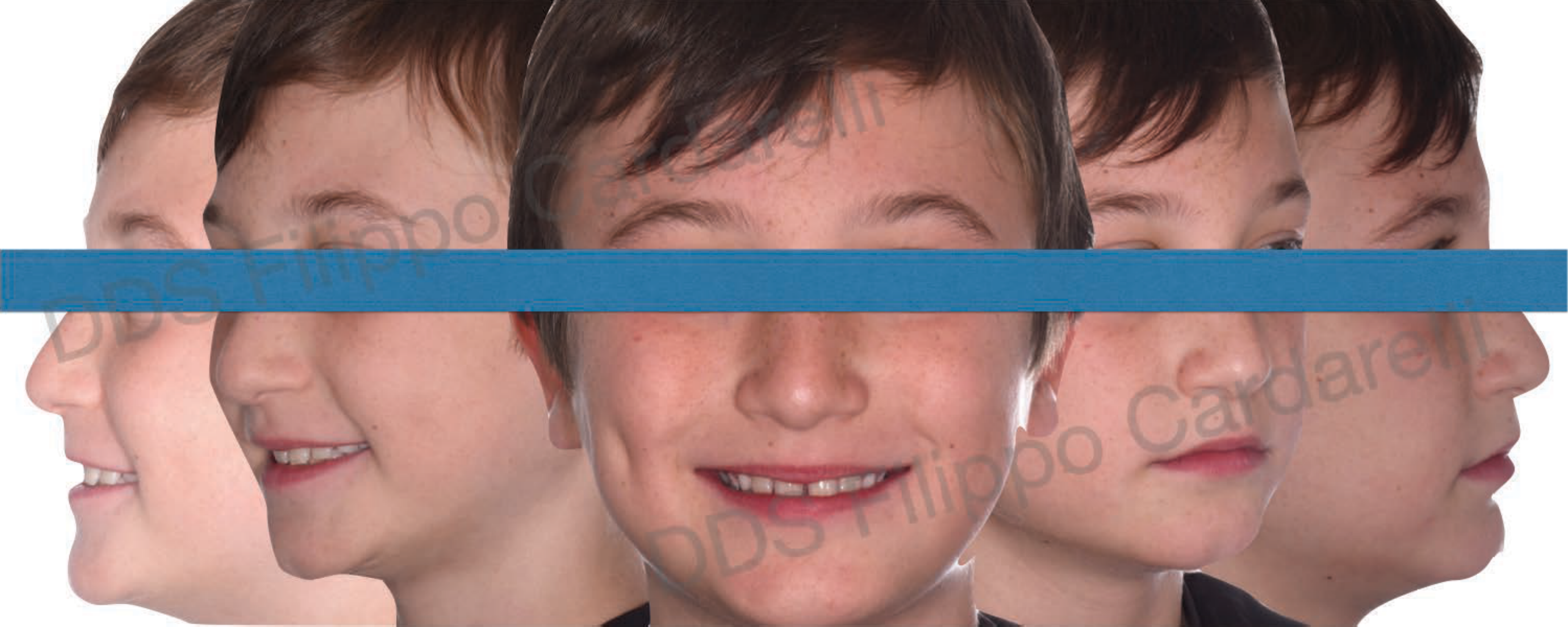DDS Filippo Cardarelli



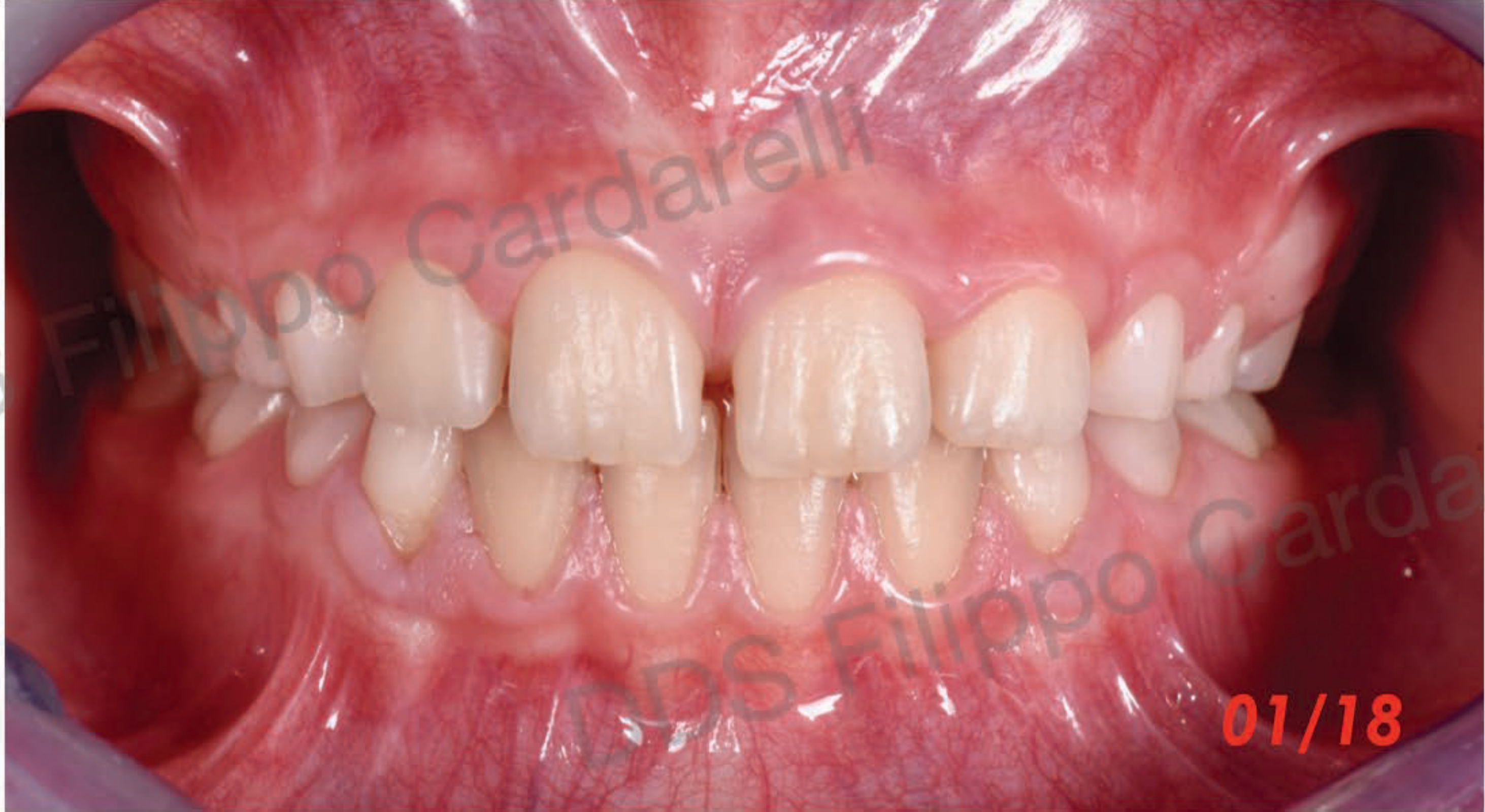# II step

The first elastodontic appliance used favored the correction of the vertical dimension but being characterized by a high anterior plane did not favor the proper coordination of the arches. At this point, therapy was continued with the AMCOP S Integral appliance with a flat chewing plane so as to promote proper maxillary development with consequent coordination of the arches themselves.

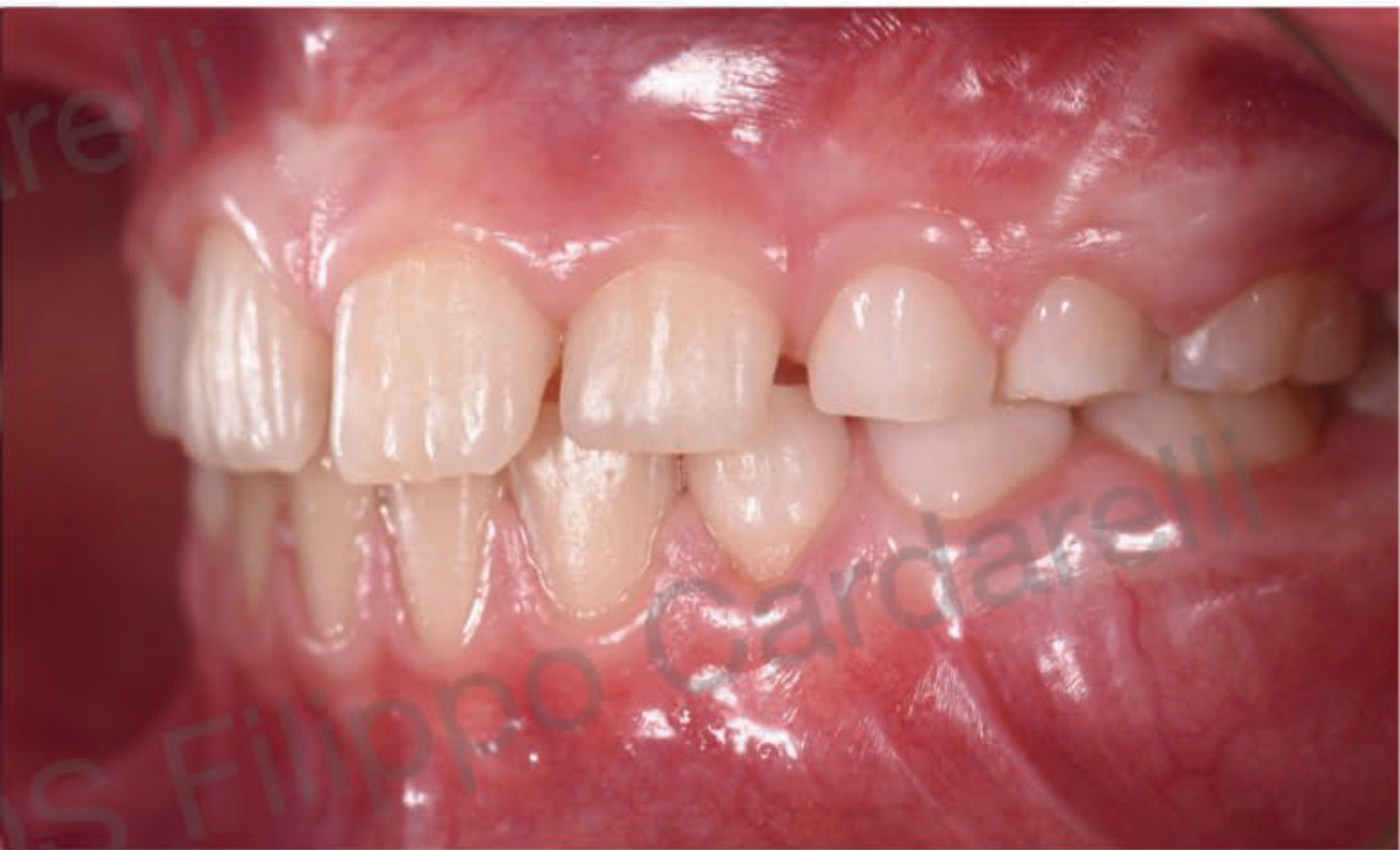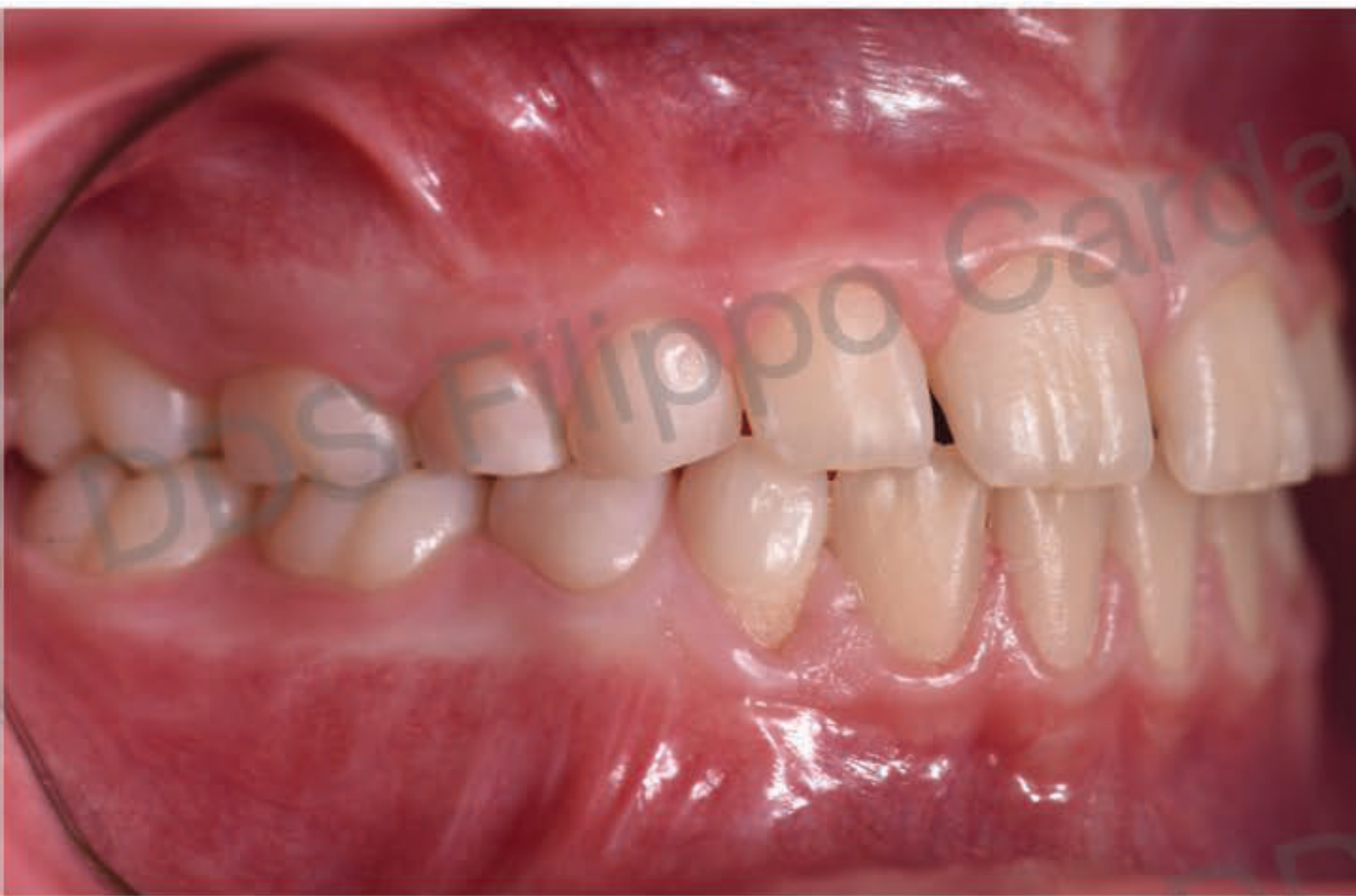Filippo Cardarelli

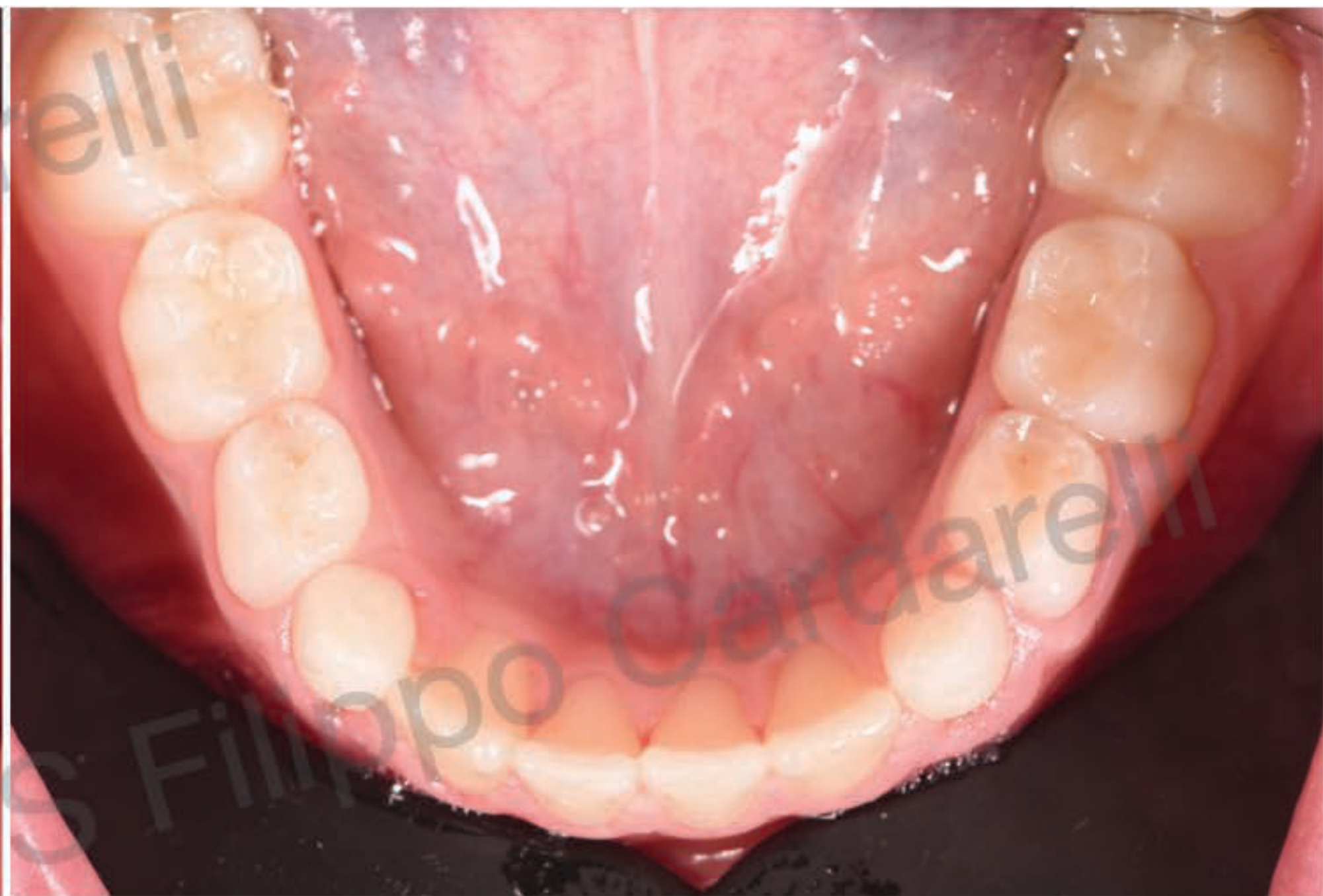
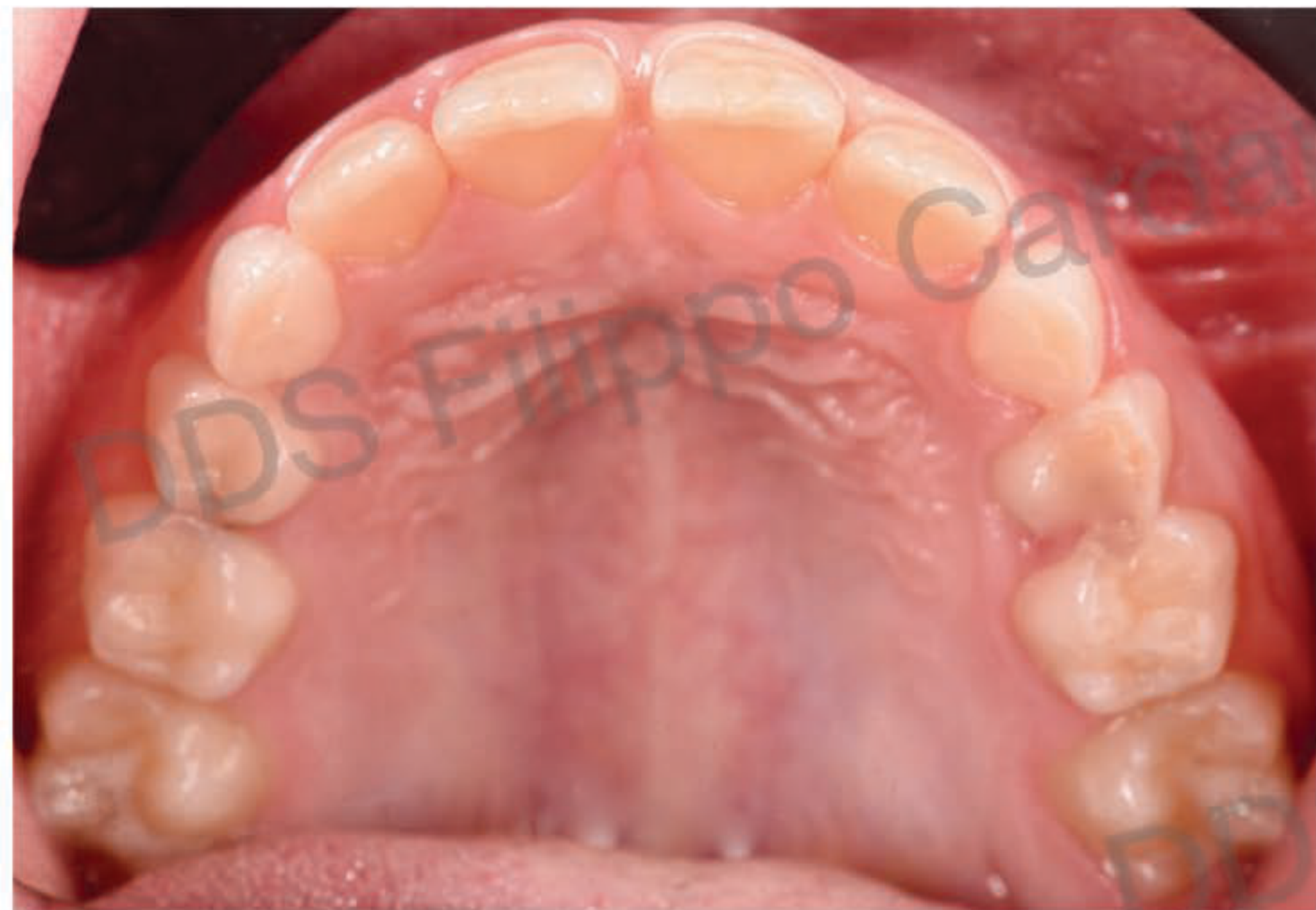
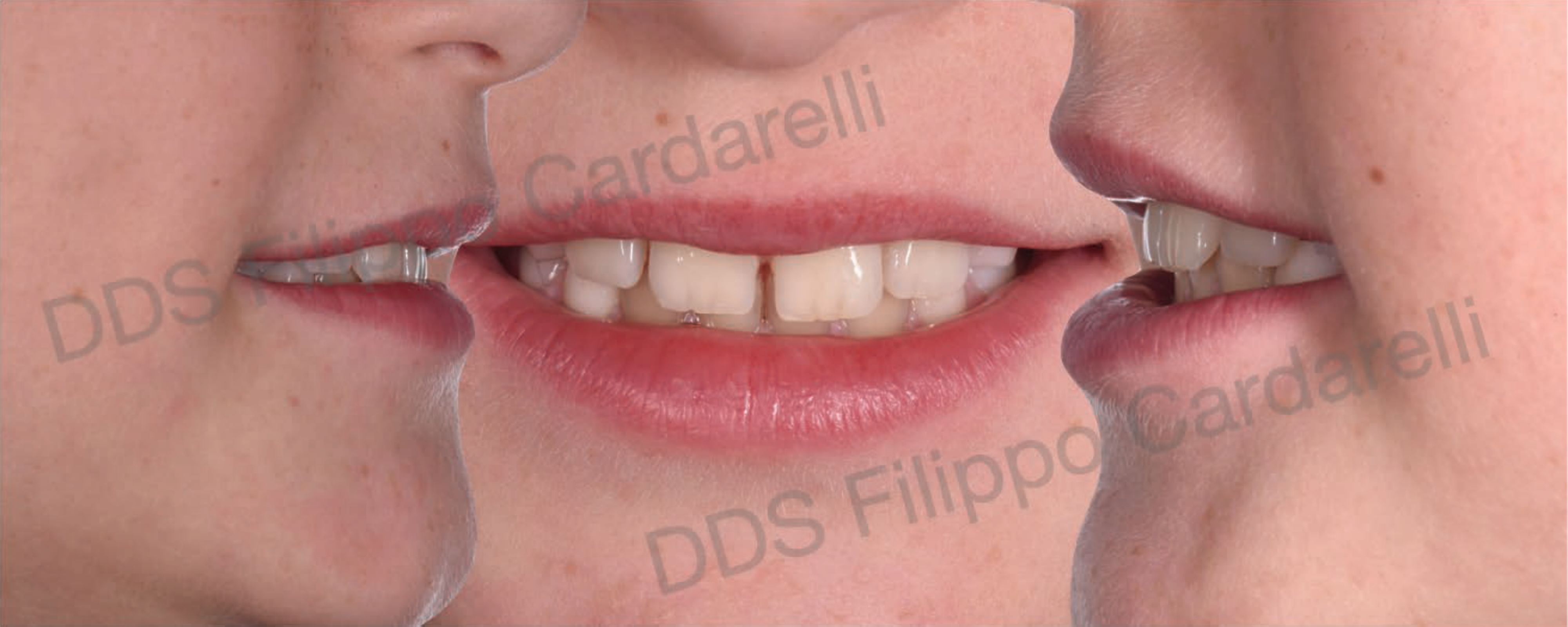DDS

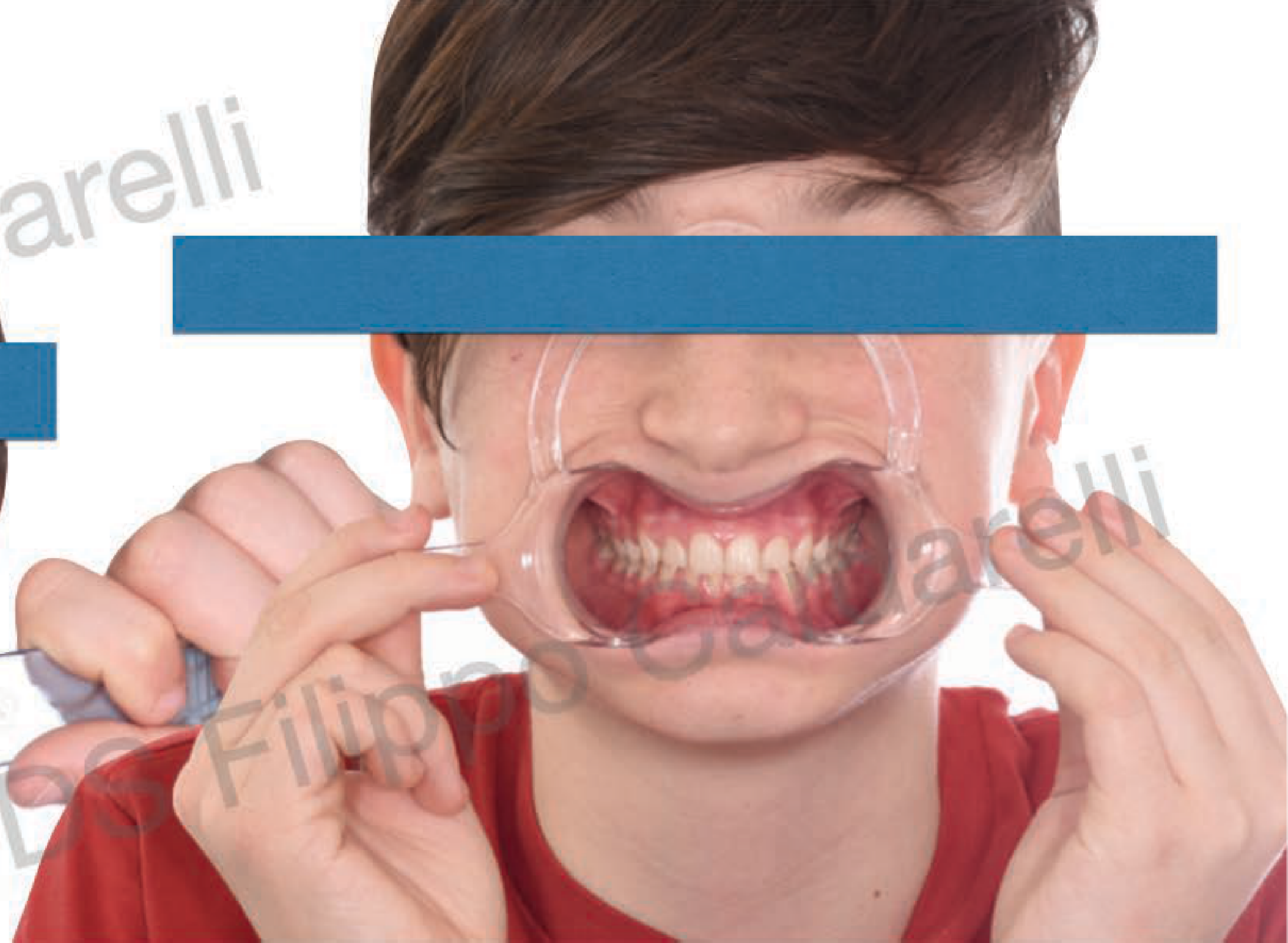
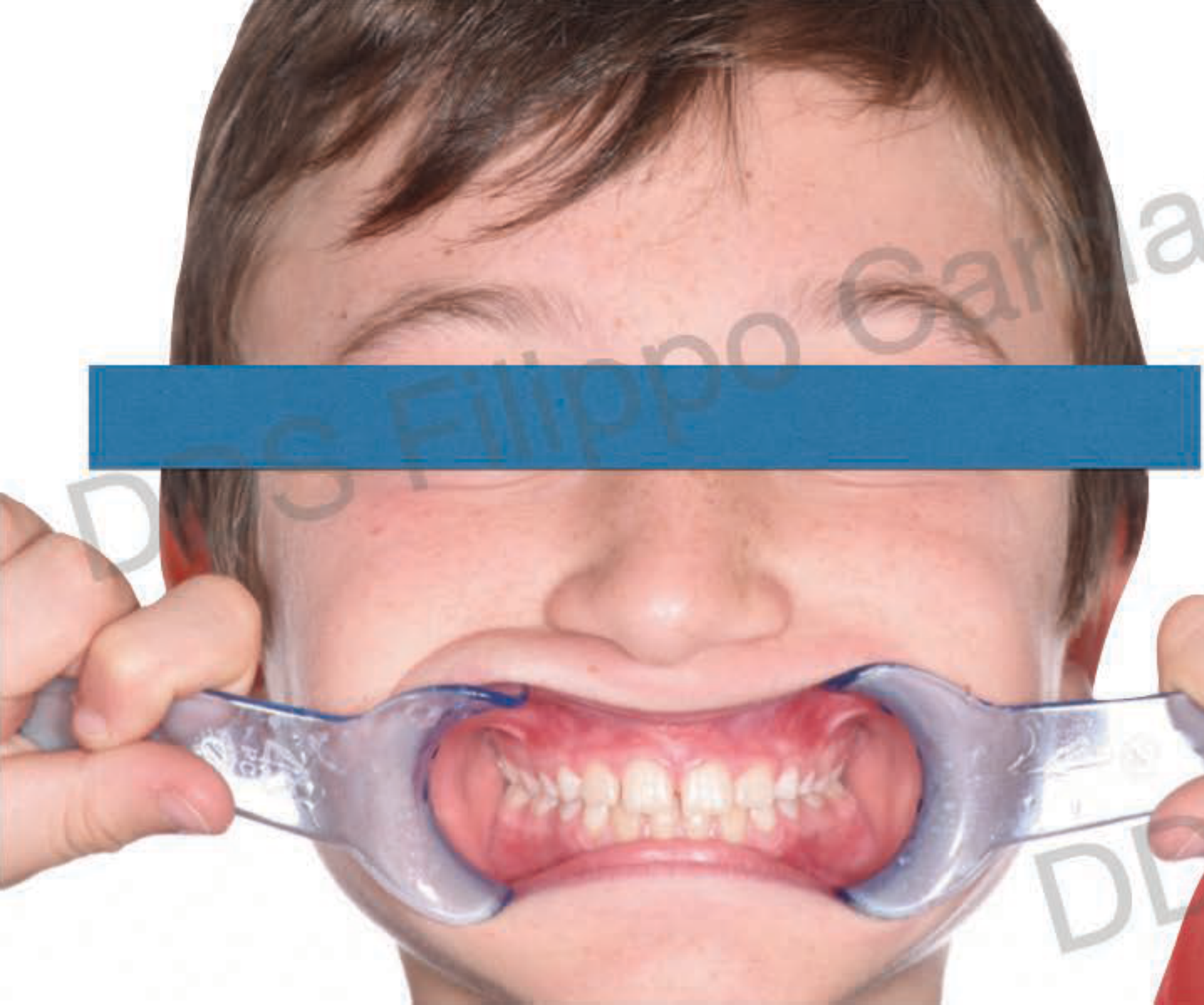
01/18



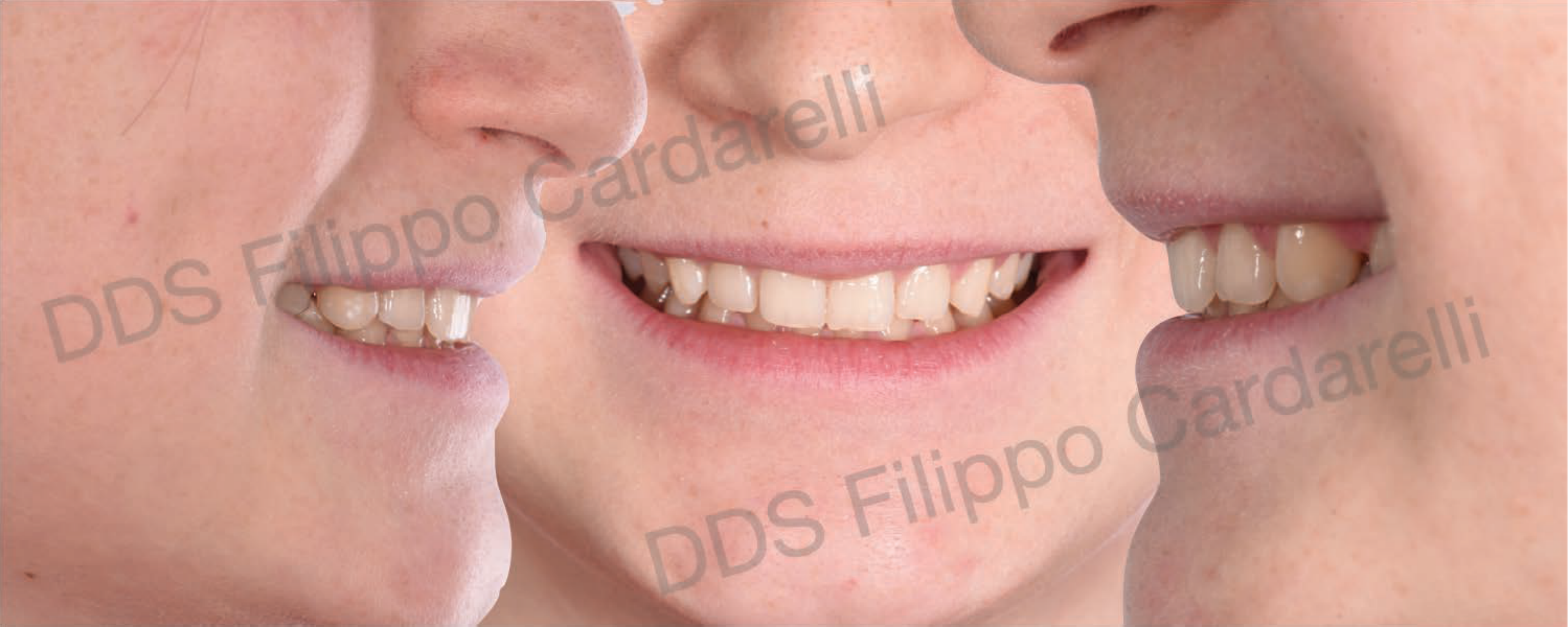


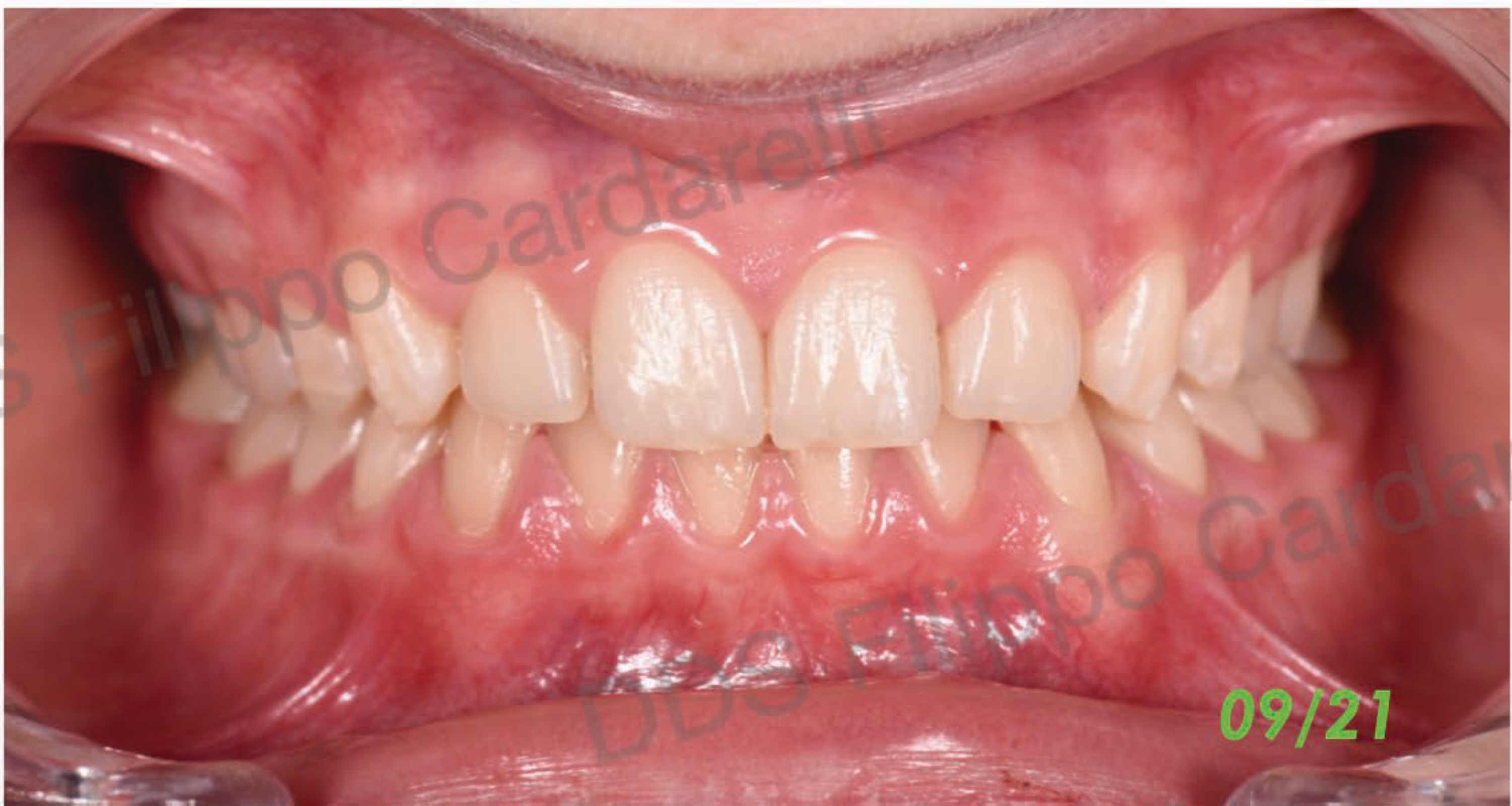










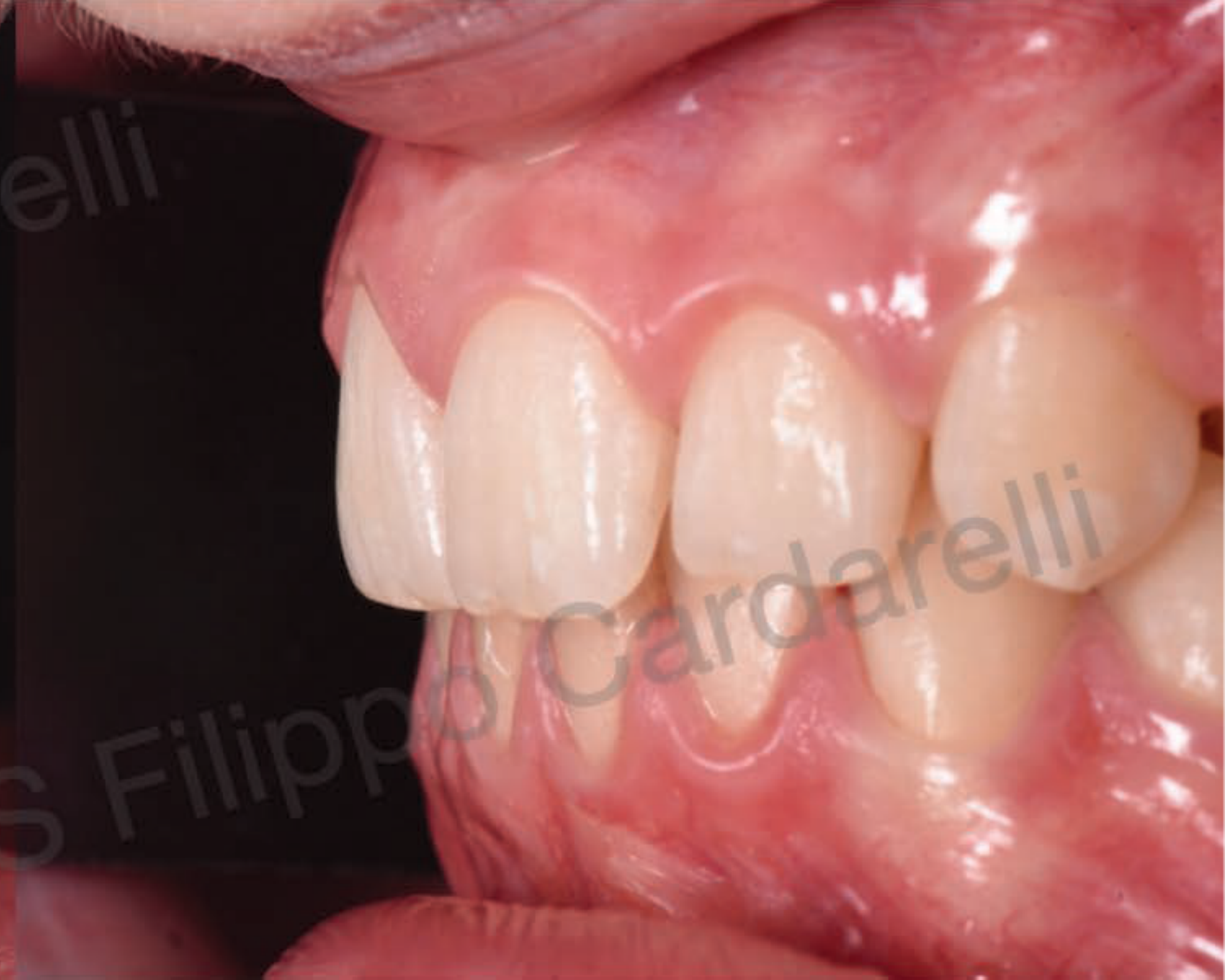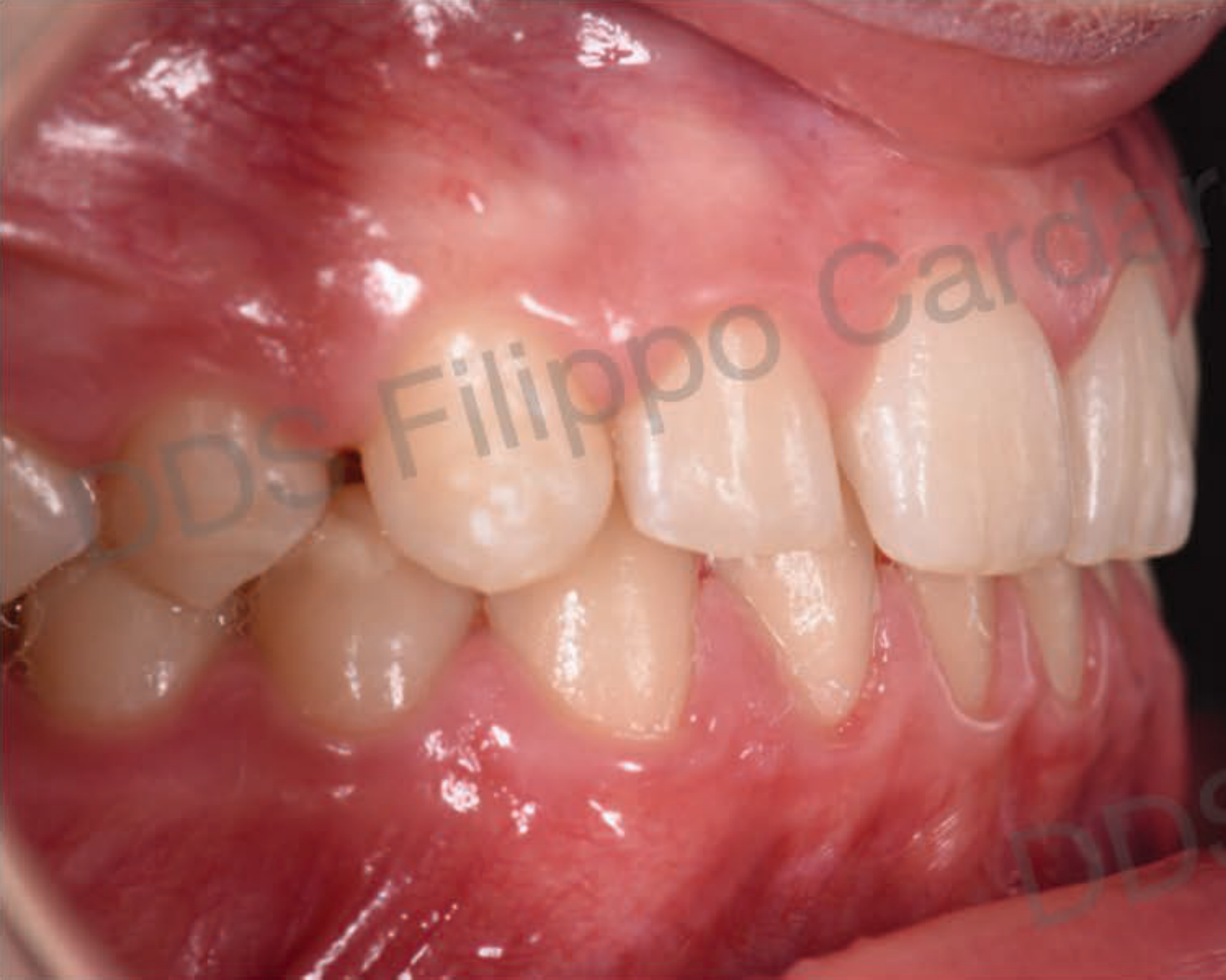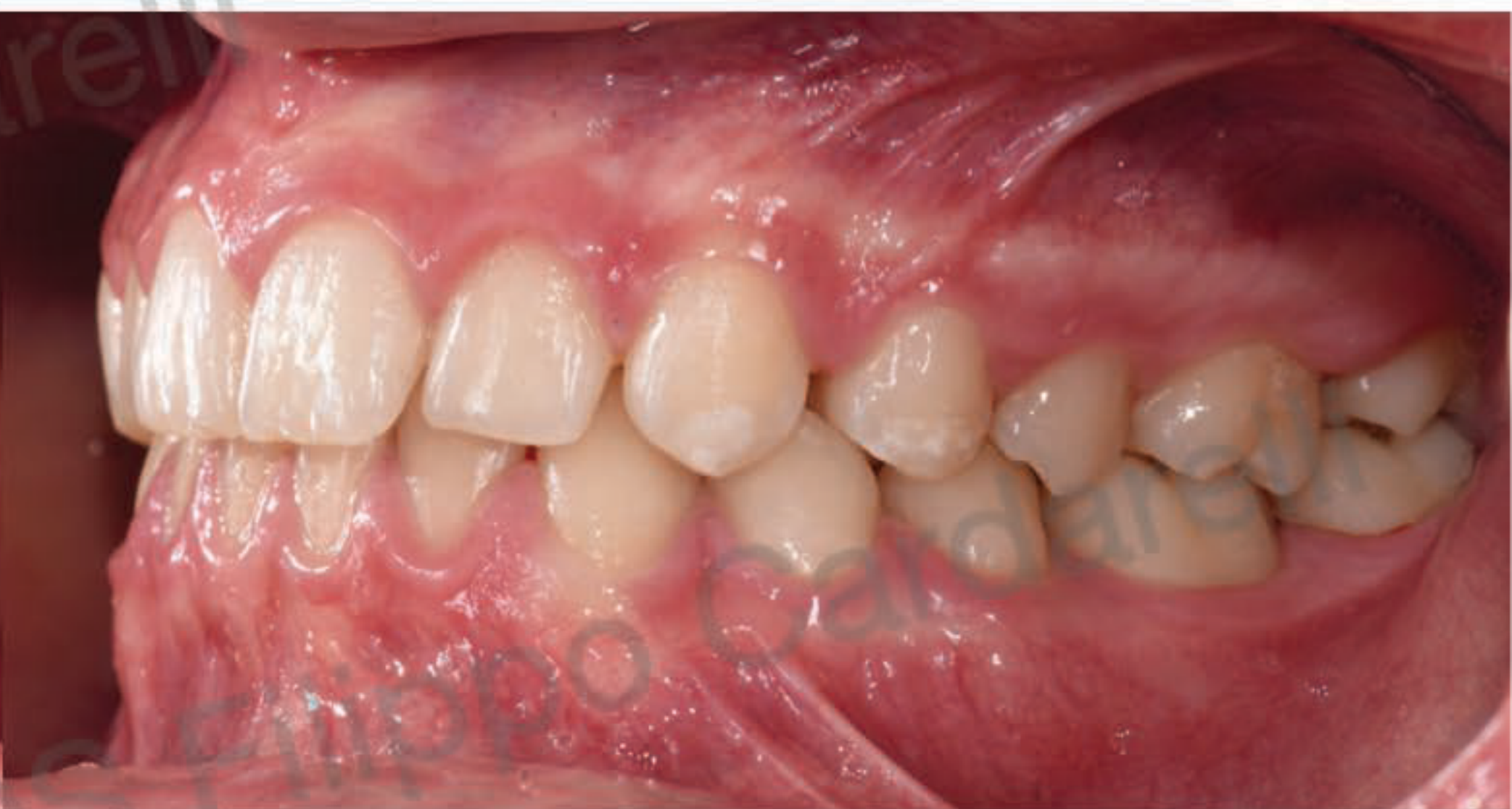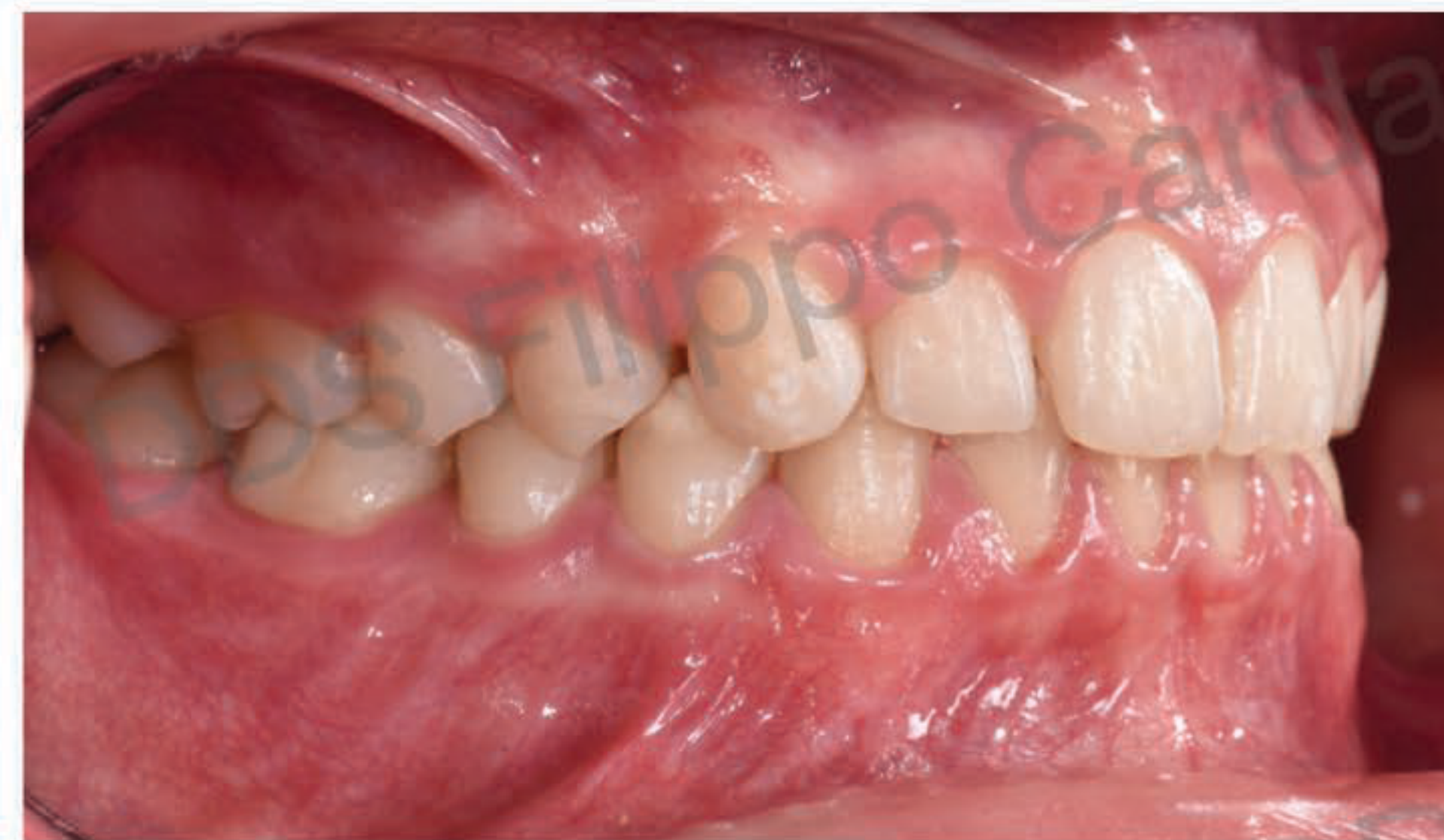DDS

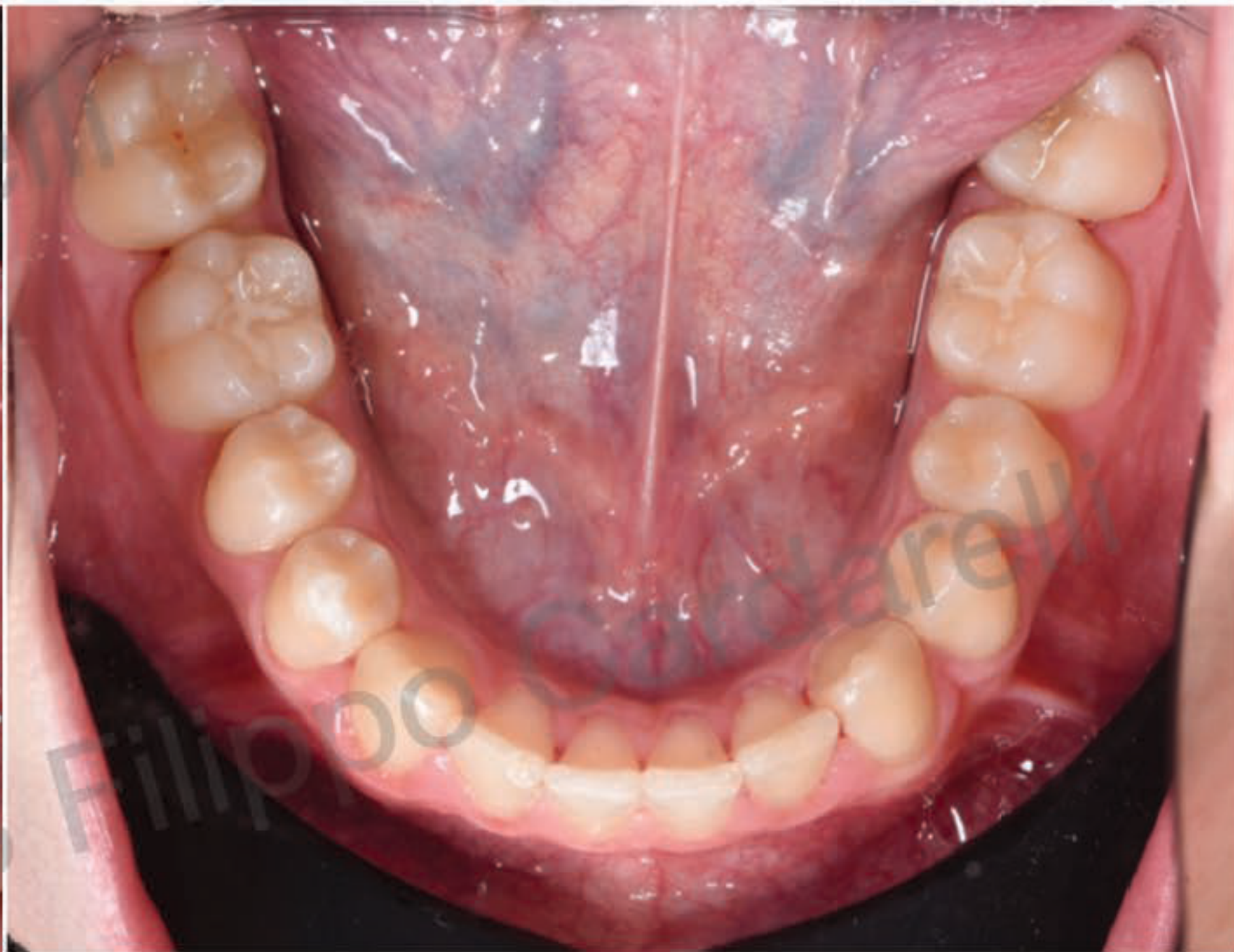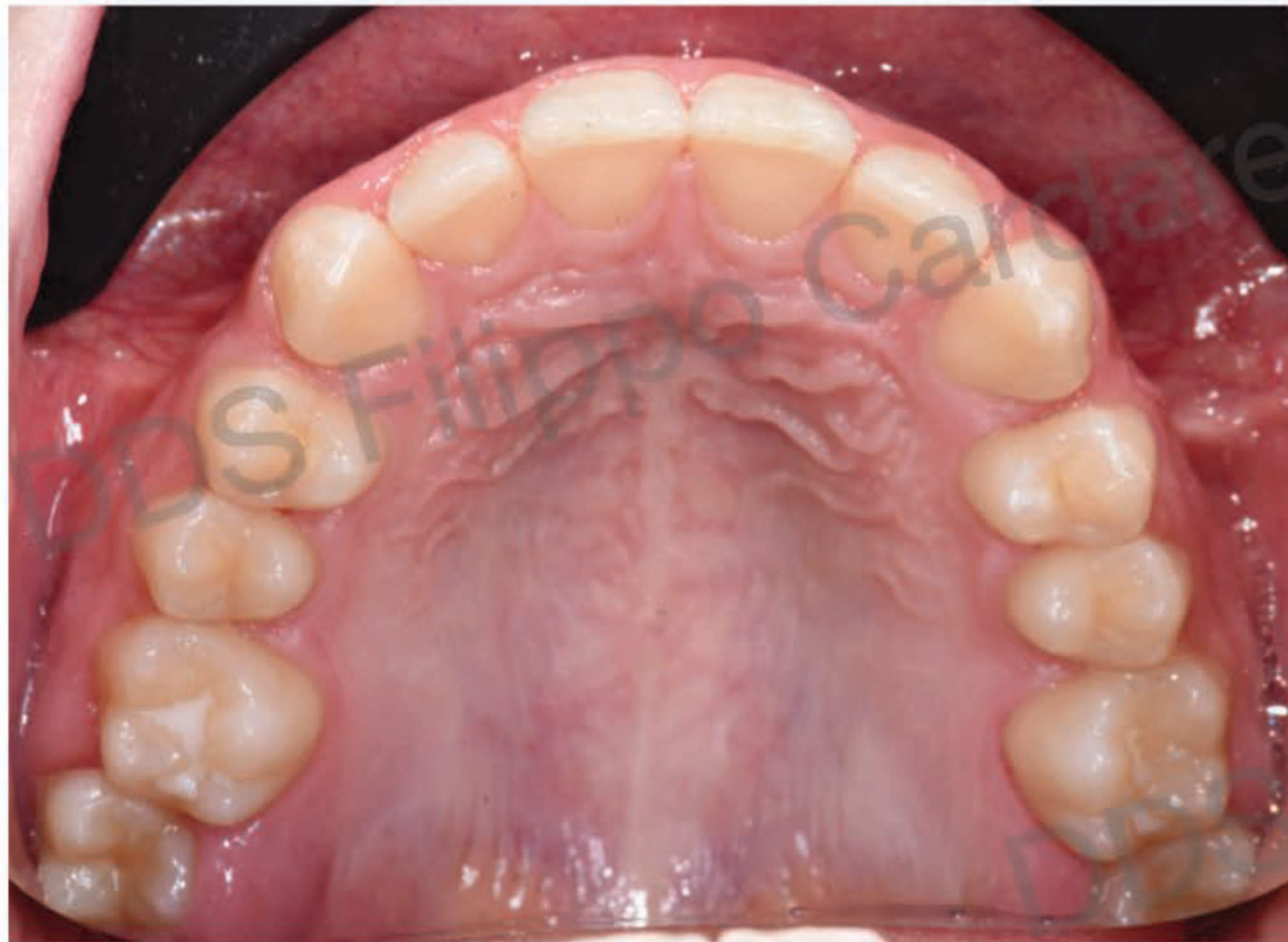Filippo Cardarelli

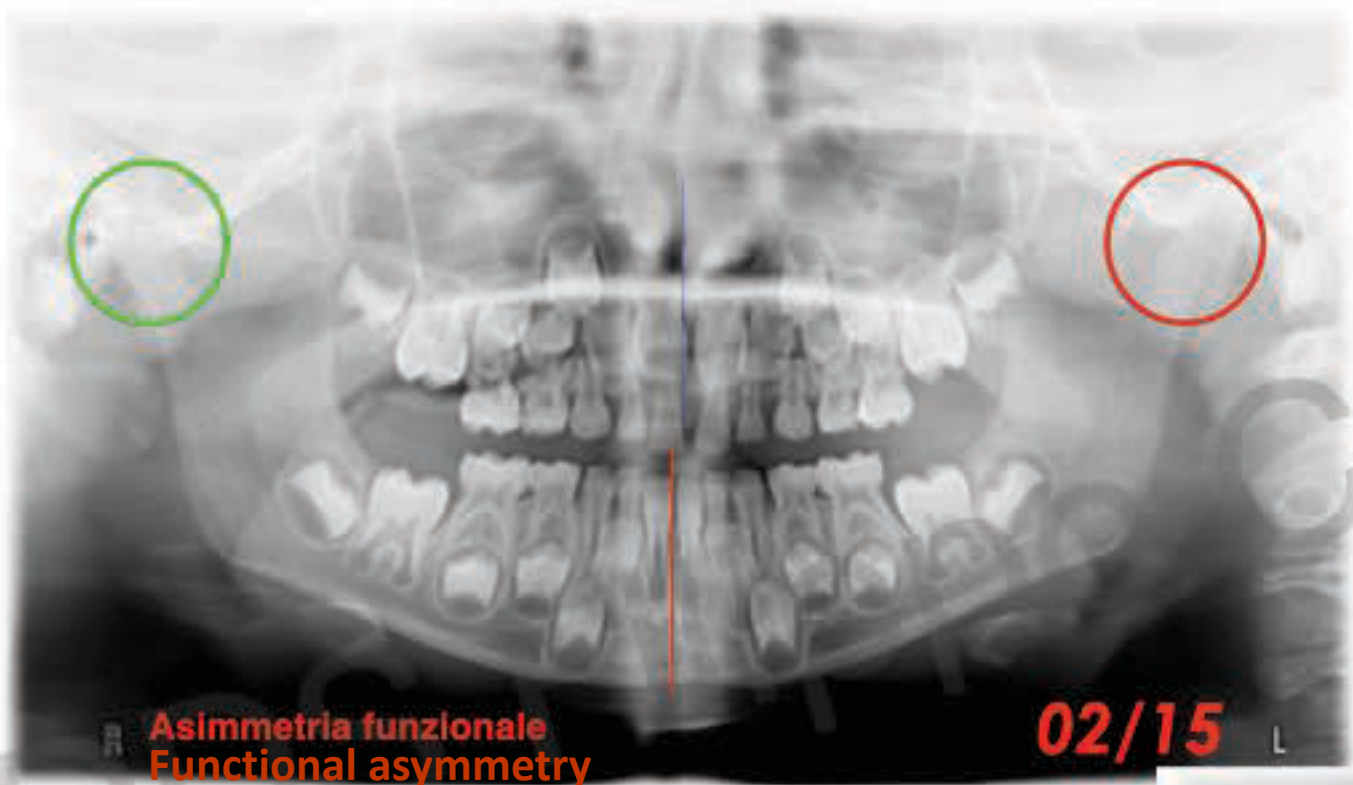
DDS Filippo Cardarelli

09/21



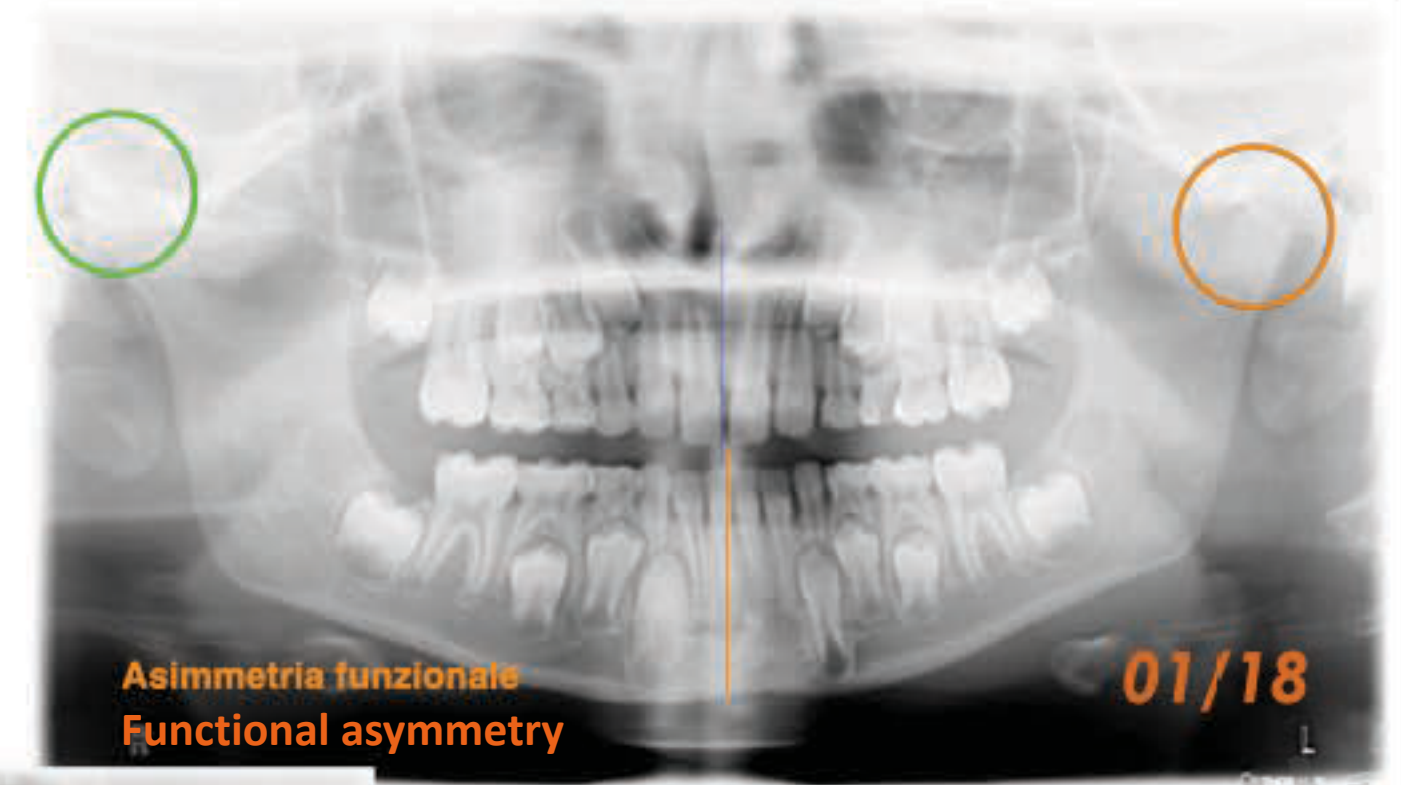






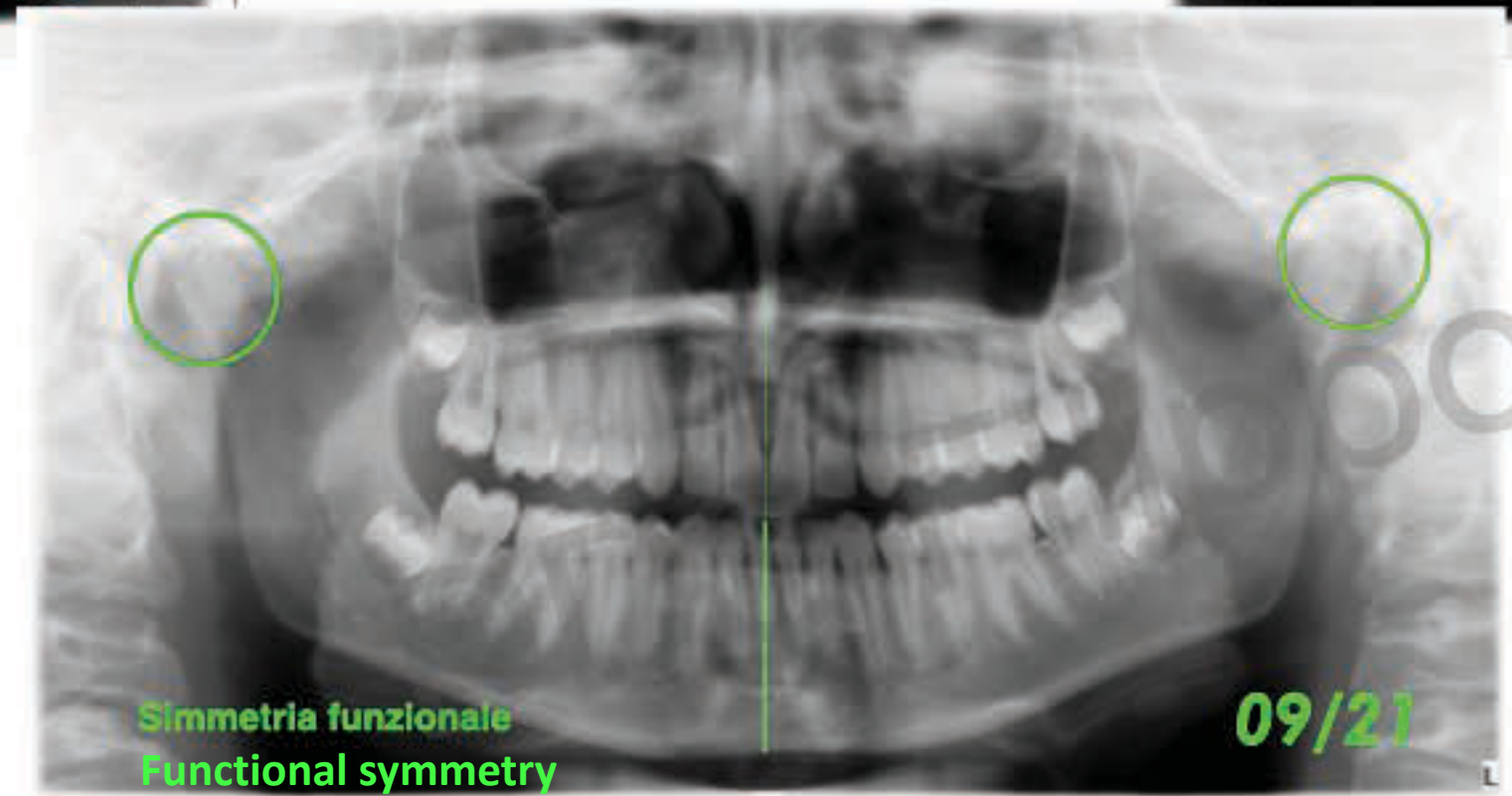
Asimmetria funzionale  
Functional asymmetry

02/15



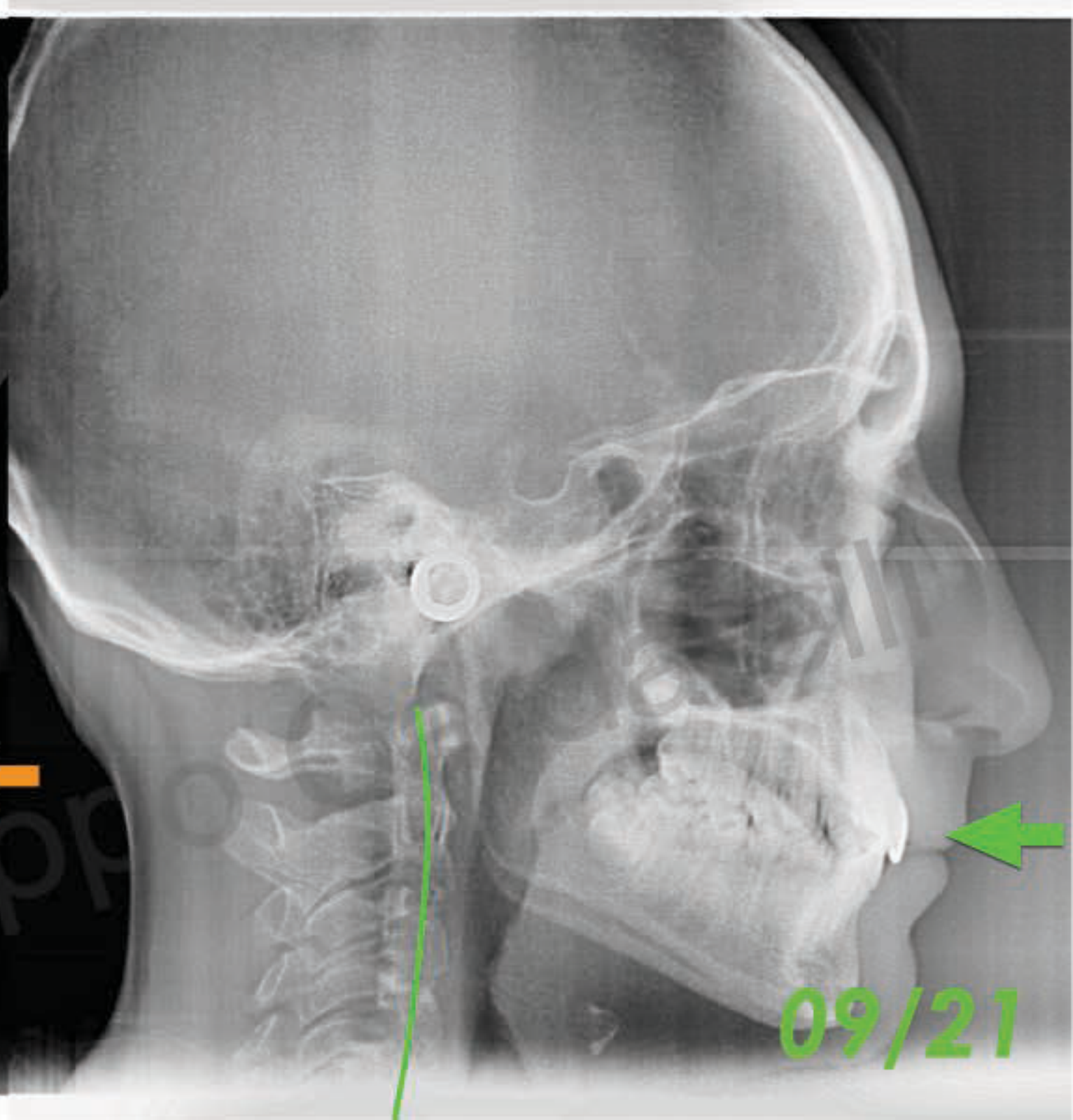
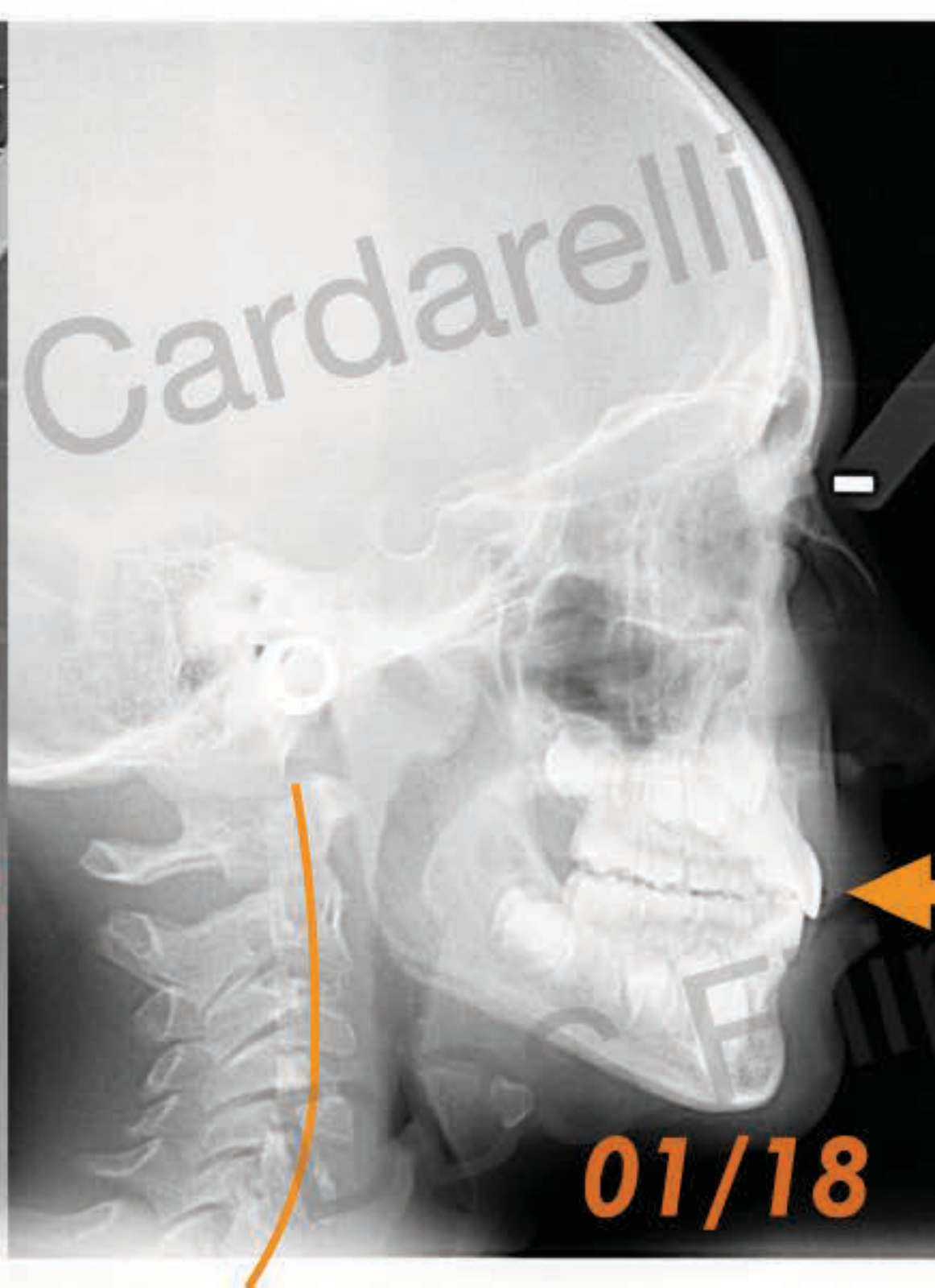
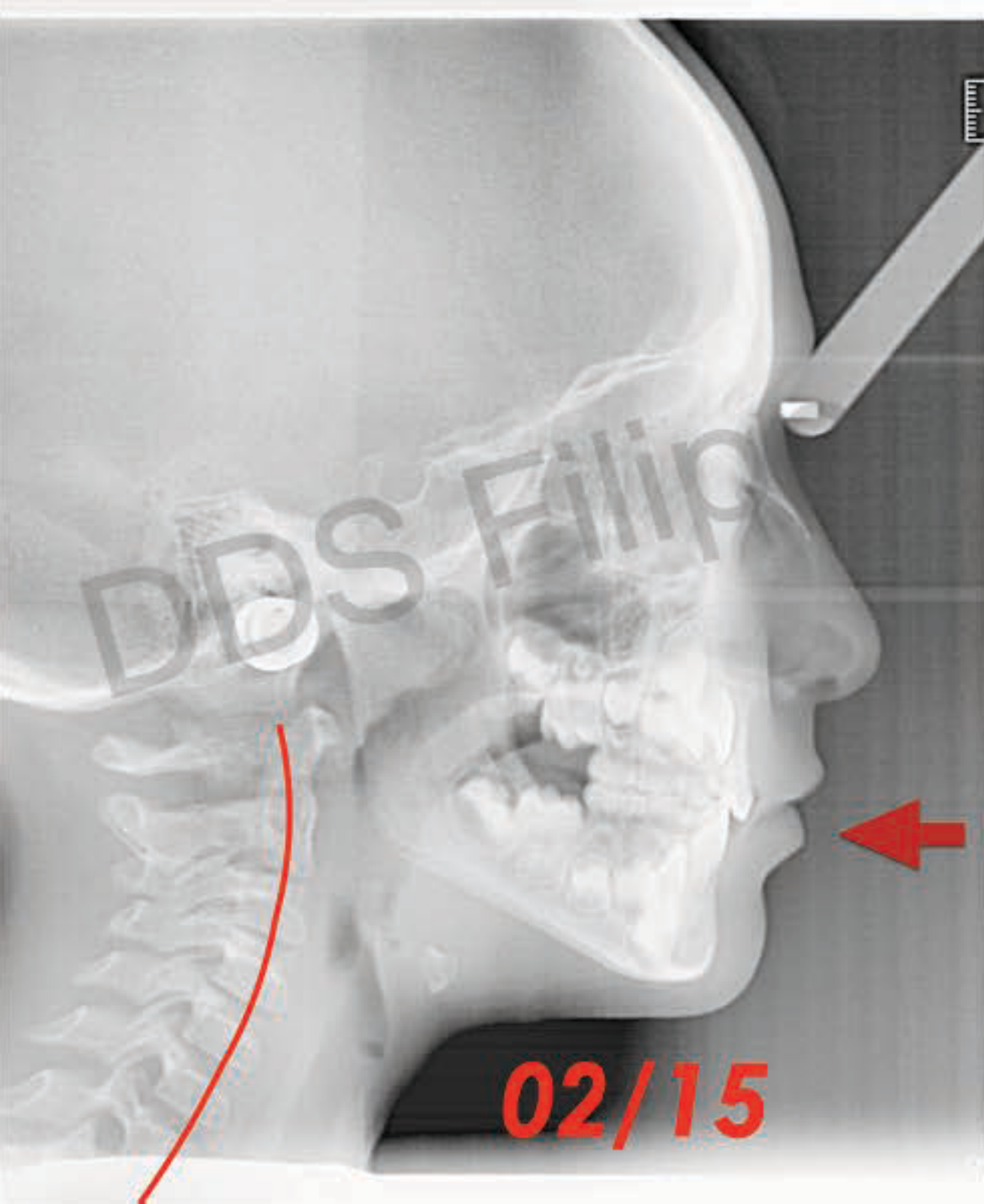
Asimmetria funzionale  
Functional asymmetry

01/18

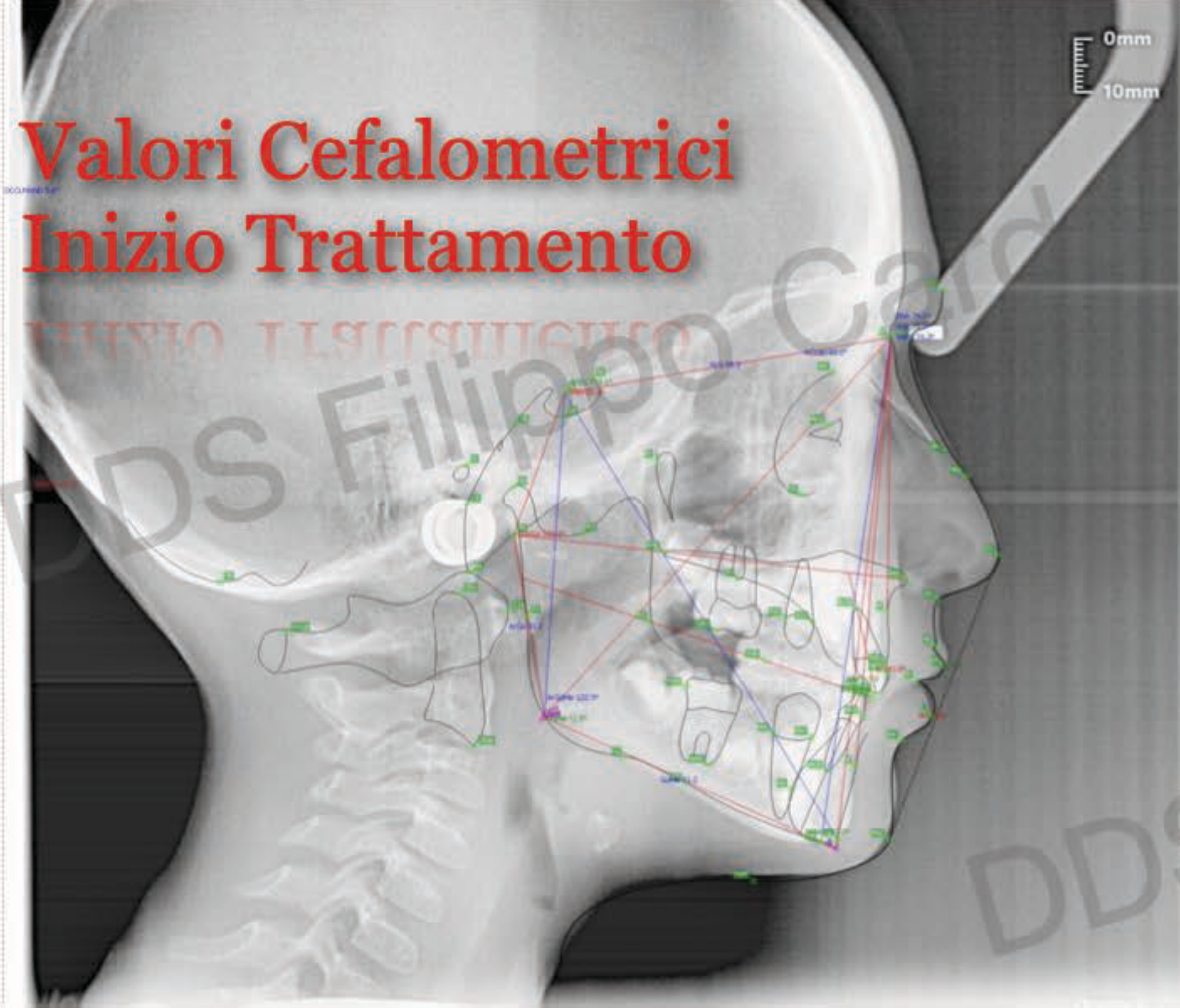

Simmetria funzionale  
Functional symmetry

09/21



# Valori Cefalometrici Inizio Trattamento

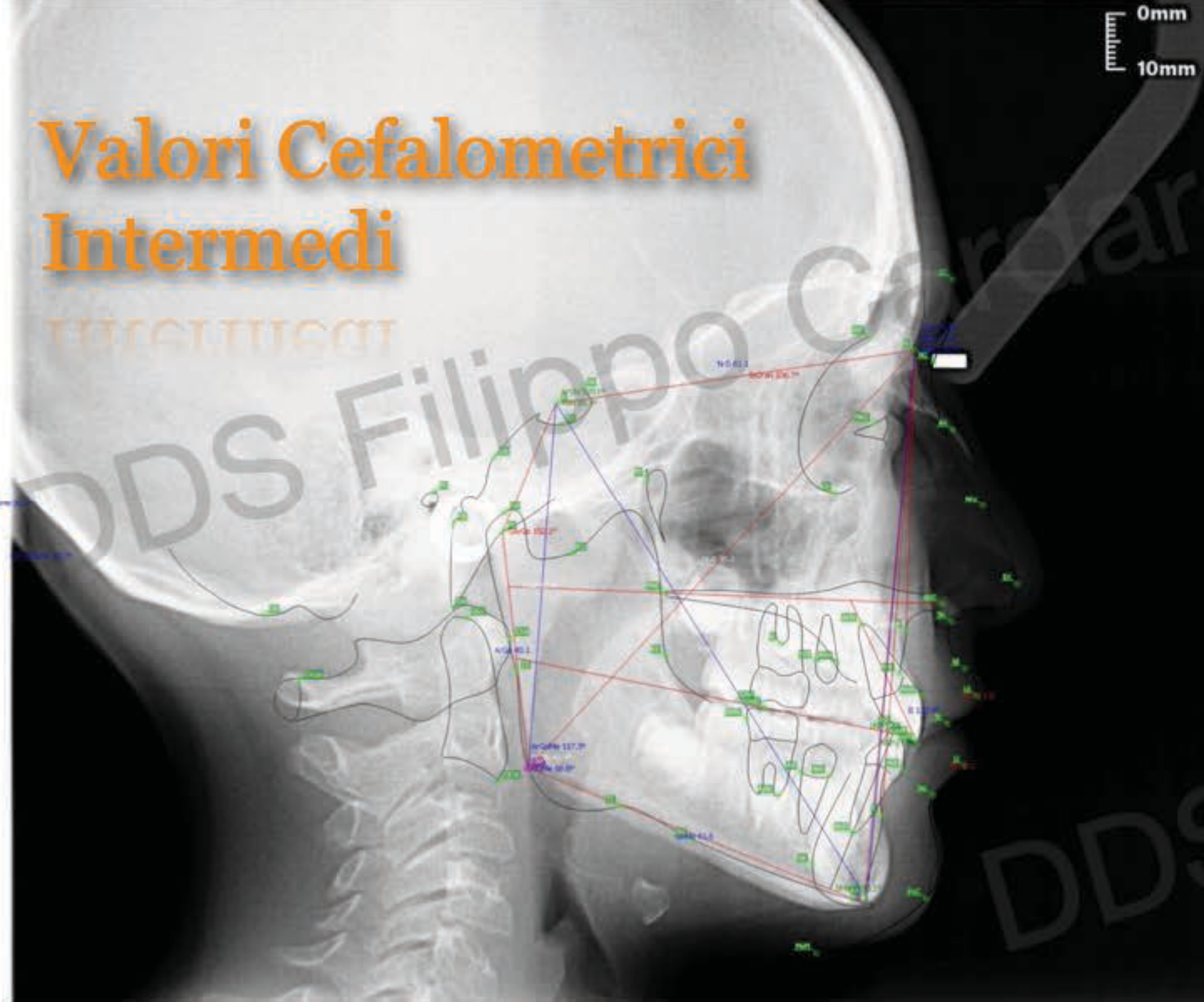


## Cephalometric Values Start of Treatment

ANB	6,0
SNA	76,00
SNB	78,00
SArGo	150,0
ArGoMe	122,00
IiMand	89,00
IsCran	93,00
II	143,00



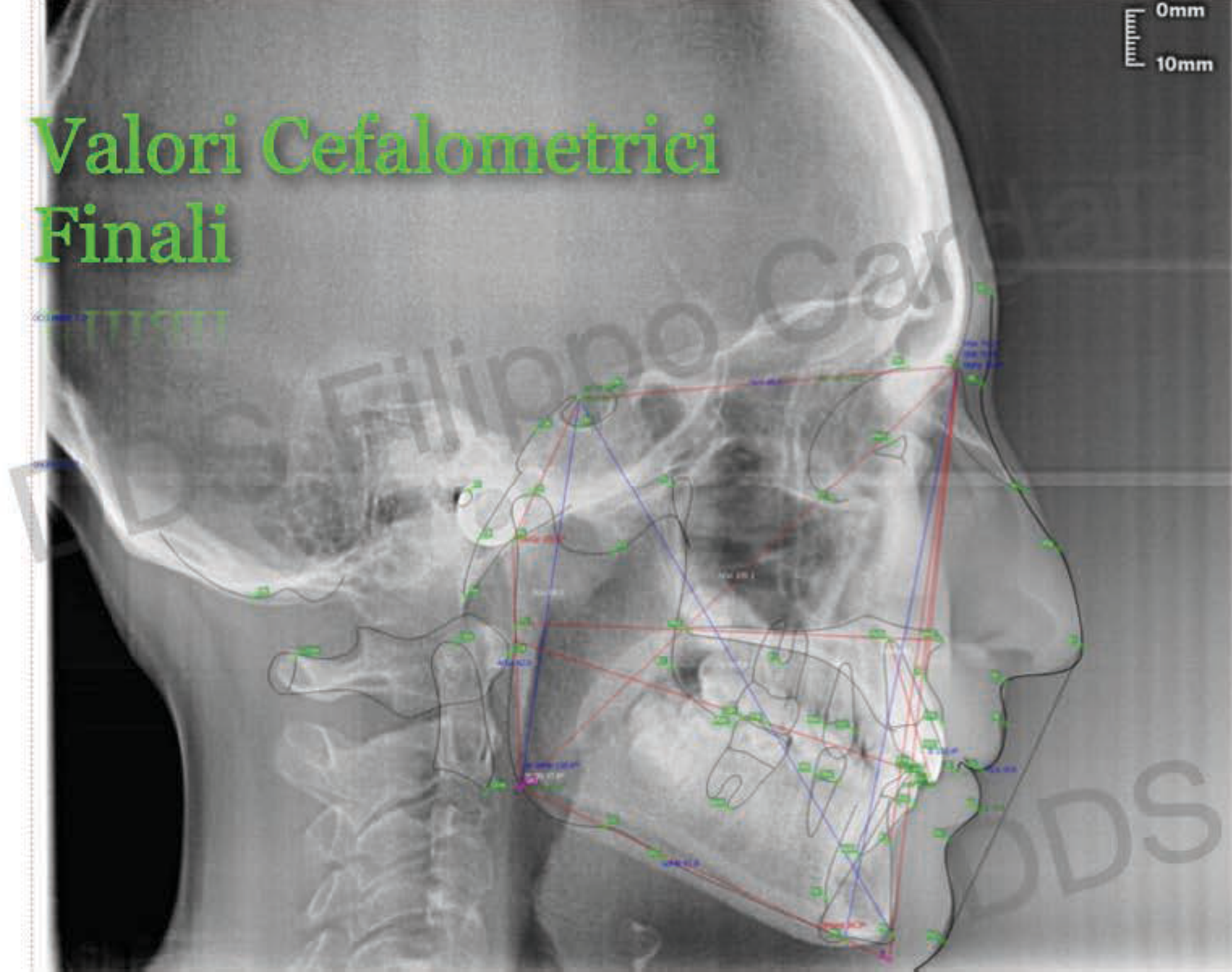
# Valori Cefalometrici Intermedi



## Intermediate Cephalometric Values

ANB	5,00
SNA	77,00
SNB	82,00
SArGo	155,0
ArGoMe	118,00
IiMand	90,00
IsCran	106,00
II	133,00

## Valori Cefalometrici Finali



## Final Cephalometric Values

ANB	2,2
SNA	79,10
SNB	76,90
SArGo	150,0
ArGoMe	116,00
IiMand	93,00
IsCran	101,00
II	132,00

# Conclusions

Class II malocclusion associated with flawed habits such as onychophagy requires early intervention in deciduous dentition and therefore through Elastodontic Therapy it is possible to achieve an irreversible skeletal and dental result and at the same time a great postural advantage as evidenced by the comparison telerradiographs that testify the normalization of the cervical curve at the end of therapy.

DDS Filippo Cardarelli

